

## A review of temporomandibular joint disease (TMJD). Part II: Clinical and radiological semiology. Morbidity processes

Rafael Poveda Roda <sup>1</sup>, José María Díaz Fernández <sup>2</sup>, Sergio Hernández Bazán <sup>3</sup>, Yolanda Jiménez Soriano <sup>4</sup>, María Margaix <sup>3</sup>, Gracia Sarrión <sup>3</sup>

- (1) Physician and dentist. Staff physician, Service of Stomatology, Valencia University General Hospital  
 (2) Maxillofacial surgeon. Staff physician, Service of Stomatology, Valencia University General Hospital  
 (3) Dentist. Private practice  
 (4) Associate Professor of Oral Medicine. Valencia University

### Correspondence:

Dr. Rafael Poveda-Roda  
 Servicio de Estomatología  
 Hospital General Universitario de Valencia  
 Tres Cruces s/n  
 46014 - Valencia, Spain  
 E-mail: [poveda\\_raf@gva.es](mailto:poveda_raf@gva.es)

Received: 5/05/2007

Accepted: 5/01/2008

### Indexed in:

-Index Medicus / MEDLINE / PubMed  
 -EMBASE, Excerpta Medica  
 -SCOPUS  
 -Indice Médico Español  
 -IBECs

Poveda-Roda R, Díaz-Fernández JM, Hernández-Bazán S, Jiménez-Soriano Y, Margaix M, Sarrión G. A review of temporomandibular joint disease (TMJD). Part II: Clinical and radiological semiology. Morbidity processes. Med Oral Patol Oral Cir Bucal. 2008 Feb;13(2):E102-9.  
 © Medicina Oral S. L. C.I.F. B 96689336 - ISSN 1698-6946  
 URL: <http://www.medicinaoral.com/medoralfree01/v13i2/medoralv13i2p102.pdf>

### Summary

The clinical signs and symptoms of greatest semiologic value in temporomandibular joint disease (TMJD) are muscle pain, joint pain, limitations in mandibular movement, and joint sounds. Imaging studies of the joint are very useful for establishing the diagnosis and for discarding other disease processes, though in many cases diagnostic error results from the detection of a large proportion of patients with alterations in the imaging studies but with no associated clinical manifestations. Panoramic X-rays and magnetic resonance imaging are the most commonly used complementary techniques for diagnosing TMJD. MRI may be regarded as the imaging technique of choice, particularly when studying the soft tissues. Biochemical evaluation of the joint synovial fluid has improved our understanding of TMJD pathogenesis, though to date such parameters have not been extended to clinical practice.

Myofascial pain with positive painful palpation of the masticatory muscles; joint disc displacements with reduction characterized by the presence of opening or opening and closing clicks; disc displacements without reduction characterized by limitations in oral aperture; and osteoarthritis / osteoarthrosis characterized by the auscultation of friction sounds during mandibular movement, are the morbidity processes most often seen in the context of TMJD. The present study offers a review of the semiology and morbidity processes of the temporomandibular joint.

**Key words:** Temporomandibular dysfunction, myofascial pain, disc displacement with reduction, disc displacement without reduction, osteoarthritis, osteoarthrosis.

### Clinical semiology

Pain is the most important symptom in temporomandibular joint (TMJ) dysfunction for both the patient and the clinician, and is the main reason why patients with TMJ disease (TMJD) seek medical help.

#### Muscle pain

Muscle pain originates in the muscle fibers, tendons and fascial layers. It consists of deep somatic pain, i.e., in global terms muscle pain is characterized by a diffuse location and a poor correlation between the origin of the pain and the body zone to which it is referred.

Irradiation to the ear, mandibular angle, parietal zone, shoulder and face is common. In some cases, mandibular palpation and/or certain mandibular movements (forced opening, lateral displacements or protrusive movements) trigger acute pain that adds to the pre-existing pain. Muscle bands and/or trigger points have been described that can induce pain when stimulated. Muscle bands are defined as thin and fine muscle zones oriented in the same direction as the muscle to which they belong, but with a comparatively harder consistency. In contrast, trigger

points have no clearly differentiating morphological features.

The masticatory muscles are easily accessible to manual palpation, and some authors have standardized the zones that should be explored, and even the pressure to be applied, with the purpose of affording homogeneous diagnostic criteria for clinicians and investigators (1). This is particularly important in the light of the results obtained in studies of the reliability of muscle palpation. In comparative studies between asymptomatic and symptomatic individuals, the reliability of muscle palpation was found to be low - with a kappa index of about 0.47 in evaluating the extraoral muscles (2). The concordance when evaluating the intraoral muscles is even lower, with a kappa index of 0.27.

#### *Joint pain*

The joint cartilage lacks nerve endings, and is therefore unable to cause pain. The nerve endings are found in the periarticular soft tissues, specifically in the disc and capsular ligaments, and in the retrodiscal tissues (bilaminar zone of Rees). These are mostly free nerve endings, though some receptors with a more complex structure believed to correspond to mechanoreceptors have been identified in the lateral portion of the capsule and stylomandibular ligament.

Anbar and Gratt (3) suggest that the pain is associated to the extravascular production of nitric oxide in the region of the TMJ. This increases the sensitivity of the peripheral nociceptors while also inducing local vasodilatation that leads to the temperature rise seen in dysfunctional joints compared with the normal TMJ. Increased levels were recorded in an important percentage (75-85%) of patients presenting disc displacement with click or block, and in 100% of patients with osteoarthritis. In contrast, elevations were only seen in one out of every 10 joints in the control series (4). Since nitric oxide is a chemical mediator between the nervous system and the muscle vessels, its excess would also be related to pain of muscle origin.

Under physiological conditions, the cytokines conform a host defense mechanism mediating in immune responses - limiting tissue damage and promoting tissue remodeling. However, the elevation of local cytokine concentrations can alter immune cell function and cause tissue damage, which in the case of the TMJ could manifest as osteoarthritis, hyperlaxity and joint pain (5).

Cytokines implicated in TMJ inflammation and pain have been interleukin-1-beta (IL-1- $\beta$ ) and tumor necrosis factor-alpha (TNF- $\alpha$ ). These cytokines are associated with the most active and advanced forms of destruction of a number of joints, including the TMJ. They induce the release of enzymes that can damage the tissues (e.g., the metalloproteinases of the synovial cells and chondrocytes), and both cytokines moreover have been associated with the production of nitric oxide in certain cell lines - particularly macrophages (6).

Sandler et al. (7) have reported a correlation between the presence of interleukin-6 (IL-6) as assayed by ELISA, the degree of acute synovitis, and acute perforation of the joint disc as diagnosed by arthroscopy.

#### *Limitation of mandibular movements: functional limitation*

The mandibular movements usually evaluated in clinical practice are maximum aperture, forced maximum aperture, lateralization towards either side, and protrusion. These are bordering movements, i.e., they displace the mandible to extreme positions that have little in common with the usual kinetics of the functional mandibular movements. However, they do provide relevant information for diagnosing TMJD.

Limitation in mandibular opening or aperture may be due to a number of reasons: protective muscle contraction to protect the affected joint, or muscle spasm as the result of an increase in metabolic degradation products induced by parafunctional activity, both limit aperture with the purpose of avoiding pain. Although with difficulty, the patient is able to open the mouth a little beyond unforced maximum aperture. Traumatism and infections can produce ossifying myositis that in turn restricts joint movement and thus also oral aperture. Other causes of limited aperture of extraarticular origin are elongation of the coronoid process, Jacob's disease, fusion of the condyle to the fossa (as described in relation to rigid internal intermaxillary fixation), and true bone ankylosis as described in bimaxillary surgery for correcting anterior open bite, and in patients following multiple facial fractures (8).

There is no universally accepted standard value beyond which limited oral aperture is considered to exist. The most widely accepted limit is 40 mm of interincisal maximum aperture. The normal amplitude of such aperture is 53-58 mm. Dworkin and LeResche established a limit of 40 mm for identifying muscle pain with limited aperture, and 35 mm of unforced maximum aperture, as one of the necessary criteria for diagnosing disc displacement without reduction associated with limited aperture (1).

Mandibular lateralization in turn is determined by measuring the displacement of the interincisal line on one and the other side. Displacements of less than 8 mm are considered to be below the normal limit. The limitation of lateral movements is usually due to disc problems (displacement towards the affected side being normal, while lateralization to the healthy side is limited) and, more rarely, to extraarticular bone disorders (elongation of the coronoid process, Jacob's syndrome, extraarticular ankylosis, etc.).

Normally, these lateralization movements are not restricted in disorders of muscle origin, since they do not require muscle stretching. A little evaluated hypothesis is the possibility that continuous lateralization movements could have a deleterious effect upon the TMJ. In 2005, Pérez de Palomar et al. (9) suggested that continuous

mandibular lateralization could perforate both discs in their lateral portion and damage lateral anchoring of the disc to the condyle.

Under normal conditions, the mandibular trajectory in maximum aperture follows a vertical line. Alterations in the trajectory may comprise deviations, when at the end of the opening movement the mandible is once again centered, or deflections, when at the end of opening the midline remains deviated. Deviations are usually caused by disc alterations, and are a consequence of condylar movements to overcome the disc obstacle. Deflections in turn are usually caused by limitations in the mobility of one of the two joints (secondary to adherences, osteophytes, ankylosis, etc.). In cases where the origin of deflection is of a muscular nature secondary to unilateral spasm, protrusion movements can help clarify the diagnosis, since they show no lateralization when the underlying cause is muscular.

#### *Joint sounds*

The presence of joint sounds supports the diagnosis of internal derangement of the TMJ - though it also must be taken into account that the absence of such sounds does not necessarily imply joint normality. In effect, joint sounds are normally not produced in cases of disc displacements without reduction, or in muscle disorders. Likewise, imaging studies are able to detect joint alterations compatible with disc displacement with reduction and with osteoarthritis, in the absence of joint sounds. Clicks are brief sounds produced by mandibular movements associated to disc displacement with reduction, though click-like sounds can also be produced by joint remodeling or joint hypermobility.

Crepitants or friction sounds in turn are longer-lasting than clicks, and may accompany part of the mandibular movement cycle. They are the result of direct friction of one bone surface against another. Friction sounds are considered to be a manifestation of osteoarthritis.

Joint sounds are highly variable in one same individual - a fact that limits the reliability of sound assessment. On the other hand, the prevalence of some type of joint sound has been estimated to reach 35% in the general population; as a result, the specificity of sound testing as a diagnostic criterion is very low.

Joint sounds are detected by palpation, auscultation or sonography. Palpation is less sensitive, since some sounds go undetected; in this sense, it is useful to question the patient as to when and where he or she notices the sounds. In contrast, auscultation and sonography offer low specificity, since many accessory sounds such as friction of the hair or skin, or even blood flow in the exploratory zone, can induce false positive readings (10).

## **Complementary explorations**

### **Imaging studies**

#### *Panoramic X-rays and the TMJ*

Panoramic X-rays (orthopantomography) are very useful for global evaluation of the maxillofacial zone, but are of only limited usefulness for the precise diagnosis of TMJD. Orthopantomography does not allow adequate visualization of the relationship between the condyle and the glenoid cavity, and the condylar head often appears distorted.

Crow et al. (11) examined the usefulness of orthopantomography in evaluating the TMJ. To this effect, they subjected 100 orthopantomographs (corresponding to 45 patients with TMJD and 55 without joint problems) to the evaluation of three examiners. Intra-examiner concordance was found to be high, though inter-examiner agreement was only discrete. No differences in condylar morphology were detected between the two groups of patients, and moderate condylar changes were seen in all age groups. The authors concluded that isolated changes in condyle shape are not indicative of TMJD, and that minor condylar discrepancies may have no significance at all.

Magnusson et al. (12), in a series of 285 panoramic X-rays corresponding to patients with TMJD, reported clinically relevant radiographic findings related to the TMJ in 25% of cases, while 11% showed relevant X-ray findings not related to TMJD. The authors concluded that panoramic X-rays are of diagnostic utility in patients with TMJD.

Slightly different conclusions were drawn by Epstein et al. (13), who observed bone alterations in 43.6% of their panoramic X-ray series that did not lead to diagnostic changes in any of the patients. The authors concluded that the clinical findings are more relevant than orthopantomography in establishing the diagnosis and in defining the need for other complementary studies.

#### *Computed tomography (CT)*

Computed tomography avoids the overlapping of images that characterizes conventional X-rays, as well as the distortion effect of conventional tomography.

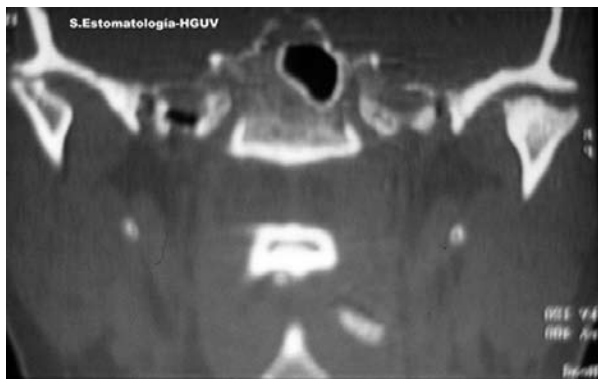While CT is very useful for studying the soft tissues, it is particularly effective in assessing bone structures (Fig. 1). The technique was initially believed to be able to evaluate the position of the joint disc, but it was found to lack the required reliability.

Controversy over this point remains, however, since some authors consider that the usefulness of helicoid CT is comparable to that of magnetic resonance imaging in detecting disc displacement with the mouth closed - offering a sensitivity and specificity of 91% and 100%, respectively (versus 96% and 99% with the mouth open)(14).

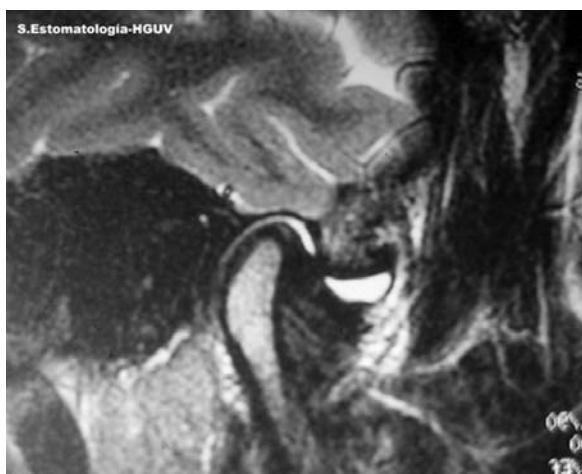
#### *Magnetic resonance imaging*

MRI is able to detect the position of the joint disc in both the coronal and the sagittal plane, and can assess the morphological anomalies and variations in its normal position. The possibility of conducting pseudodynamic and (recently) even dynamic studies of the joint allows more complete evaluation of disc alterations.

Although MRI is considered the gold standard for eva-



**Fig. 1.** Computed tomography (CT) exploration of the temporomandibular joint (TMJ). Leveling, erosion, osteophyte formation, and reduction of the joint space.



**Fig. 2.** Joint effusion as evidenced by magnetic resonance imaging (MRI). The effusion corresponds to the more hyperintense zone.

luating disc position, it must be taken into account that in up to one-third of all asymptomatic persons the disc appears displaced anteriorly. Therefore, as regards the position of the joint disc, MRI is highly sensitive, but of more limited specificity.

Under normal conditions, the meniscus is seen as a dark band located between the upper condylar pole and up to 90° anteriorly (between the 12 and 3 o'clock positions). Variations in position may be both anterior and lateral, though in the latter case there is controversy over whether this constitutes true posterior displacement (difficult to account for in biological terms) or metaplasia of the retrodiscal tissues (15).

The observation in MRI scans of hyperintense images in T2-weighted sequences in the anterior articular recesses of the upper and lower compartments, identified as signs of joint effusion (Fig. 2), has been the subject of many studies to determine the value of such findings as a sign

of joint inflammation. This is based on the hypothesis that while the presence of synovial fluid is normal in the joint in small amounts (barely detectable in imaging studies), the excessive accumulation of such fluid would be indicative of synovial tissue response to an inflammatory stimulus. Suenaga et al. (16) reported joint effusion in up to 9% of asymptomatic individuals.

Guler et al. (17) in turn found no correlation between pain and dysfunction on one hand and joint effusion on the other, after using MRI and arthrocentesis to study 15 healthy individuals and 16 symptomatic patients.

Sener et al. (18), after studying 200 patients, observed a significant relationship between effusion and disc deformity, subluxation and degenerative changes.

Manfredini et al. (19), in an evaluation of the predictive value of the clinical manifestations in relation to joint effusion in 61 patients with TMJ pain, found the best predictor of effusion to be palpation of the lateral pole of the TMJ, with a precision of 76.2%.

### Biochemistry of synovial fluid

In human subjects, Guler et al. (17) analyzed the synovial fluid of 16 patients and 15 controls, and found statistically significant differences in the mean total protein concentrations. Although a positive correlation was recorded between the degree of joint effusion and total protein concentration, no correlation was found between the level of pain and joint dysfunction or derangement and the total protein concentration in synovial fluid.

Kaneyama et al., in the University of Ishikawa (Japan), conducted a detailed study of the synovial fluid proteins of the TMJ - particularly as refers to the presence of proinflammatory cytokines. In the year 2002, they published a study (20) in which these substances were assayed by enzyme-linked immunosorbent assay (ELISA). The authors found that the levels corresponding to cytokines IL-1 $\beta$ , IL-6, IL-8 and TNF- $\alpha$  (Tumor Necrosis Factor-alpha) were significantly higher in the study group than in the controls, and that the concentration of IL-6 was significantly higher in patients with degenerative changes than in the rest of patients. However, no correlation was found between cytokine concentration and the presence of symptoms.

Chang et al. (21) determined the levels of IgA, IgG and  $\beta$ -glucuronidase in the synovial fluid of 20 patients with severe pain and limitation of mandibular movement, and compared them with 13 healthy individuals. The concentrations of IgG and  $\beta$ -glucuronidase were found to be significantly higher in the patients than in the controls. The authors suggested that high immunoglobulin levels in the joint could trigger an intense inflammatory reaction, with tissue destruction secondary to the depositing of immune complexes.

In 2005, Arinci et al. (22) studied known mediators of pain, inflammation and tissue damage, such as prostaglandin

E2, leukotriene B4, malondialdehyde (MDA) (a mediator derived from arachidonic acid metabolism), nitric oxide (NO) and myeloperoxidase - attempting to relate them not only to the presence of disease but also to the severity of the latter. They used the Wilkes classification of TMJ derangement, which relates the arthroscopic findings to the clinical and radiological observations. Nitric oxide was seen to be the mediator showing the earliest changes, with significant increases from stage II (intense and late clicks, disc deformity, 50-80% roofing (i.e., the portion of the condyle covered by the disc), and synovitis). In stage III (pain and hypersensitivity with a decrease in aperture, disc deformity, 5-10% roofing, prominent synovitis and incipient signs of chondromalacia) they moreover found elevations in PGE2, leukotriene B4 and myeloperoxidase. Significant elevations in malondialdehyde were only recorded in stage IV (chronic pain, hard tissue degenerative changes, and grade III and IV chondromalacia).

Bradykinin, a potent inflammatory mediator, has also been investigated in relation to the TMJ. Suzuki et al. (23) studied this mediator in 33 synovial tissue biopsies corresponding to 31 patients with internal derangement of the joint, and in 20 synovial fluid samples from 18 patients with internal derangement. The authors identified bradykinin in the synovial bed, and the levels in synovial fluid were found to be higher in the patients than in the controls - though no statistically significant correlation could be established.

## **The most common morbidity processes**

### **Muscle disorders**

With minor variations, all current classifications of TMJD distinguish between muscle disorders and joint derangement. The disease processes included in the group of muscle disorders shows a degree of variability. Thus, the classification developed by Bell, which is taken as reference by many authors, does not include the concrete diagnosis of myofascial pain - although this condition is effectively included in the classification used by Okeson (based on the Bell classification, with some modifications), Kaplan and the American Academy of Orofacial Pain (AAOP). Dworkin and LeResche, among their research diagnostic criteria for temporomandibular disorders (RDC/TMD), include only myofascial pain with or without limited aperture in their classification - though they indirectly include other processes such as muscle spasm, myositis and contracture, which they define clinically in order to avoid their inclusion in the muscular diagnostic section of the RDC/TMD.

### **Myofascial pain**

Myofascial pain is also known as painful myofascial head and neck syndrome, or trigger-point myalgia.

The term myofascial pain was first used by Travell and Rinzler.

In the original description, myofascial pain is defined as a regional myogenic disorder originating in hypersensitive areas of the muscles known as trigger points. These points correspond to a circumscribed zone in which only a few motor units contract (as a result of which muscle shortening does not occur).

These zones are the origin of deep and constant pain. As a result of the latter, the trigger zones can induce central excitation phenomena, neuroplasticity and referred pain secondary to the excitation of groups of convergent interneurons.

Muscle pain is the main symptom of myofascial pain, but not the only one. The condition can be associated to secondary hyperalgesia (e.g., hyperesthesia of the scalp), vegetative effects such as lacrimation or ocular dryness, vascular alterations with paleness or reddening, or protective co-contractions of other muscles. In any case, these manifestations are of a unilateral nature, which is of great help in establishing a differential diagnosis.

Dworkin and LeResche, in section Ia of their classification, define myofascial pain as pain of muscle origin, associated with pain and sensitivity in response to muscle palpation. The diagnostic criteria include pain of the mandible, temples, face, region anterior to the ear and within the ear, occurring under resting conditions or during activity. In addition, the diagnosis requires the induction of pain in response to the palpation of three or more muscle points out of a total of 20 points. In addition, at least one of the painful points must be located on the same side where the patient reports spontaneous pain. Section Ib of the classification corresponds to myofascial pain with limited oral aperture. In addition to the criteria commented above, the diagnosis in this case includes active aperture of less than 40 mm, with passive maximum aperture at least 5 mm greater than active aperture.

### **Joint disc alterations**

Disc displacement refers to the situation in which the joint meniscus is not located in its normal position. The term sometimes has been used as a synonym for internal derangement of the TMJ.

The etiology underlying disc displacement remains unclear (see the first part of this work). Attempts to relate the condition to occlusal or orthodontic factors or to para-functional habits have yielded conflicting results. Thus, while some authors have observed an association between these factors and disc displacement, other investigators have reported the opposite. In 2001, Dorrit-Nitzan (24) suggested that displacement occurs as a consequence of degradation of the joint lubrication mechanisms. According to this author, harmonic disc transference takes place thanks to the presence of phospholipids and hyaluronic acid that conform the lubrication system of the TMJ. The phospholipids are intimately bound to the joint surfaces, and act as extremely effective lubricants.

Recently, it has been shown that hyaluronic acid adheres to the phospholipids of the joint surfaces, protecting them from lysis induced by the phospholipase A-2 generated by the synovial cells. Therefore, hyaluronic acid is currently considered to be very important in protecting the joint lubrication systems.

Disc displacement is usually anteromedial; as a result, in oblique sagittal MRI projections, the posterior margin of the disc is seen to lie more anterior than the 12 o'clock position. In coronal projections, it is seen that the meniscus does not completely cover the upper margin of the head of the condyle; instead, it appears displaced towards the internal zone of the joint.

The joint meniscus can also displace laterally or posteriorly.

Although widely described in the literature, posterior displacement of the disc is questioned by some authors who, on the basis of the work of Scapino (25), consider that what is described as posterior displacement actually corresponds to the anterior portion of the posterior insertion of the meniscus - which in the case of internal derangement appears between the articular surfaces of the condyle and temporal bone, with a more compact appearance and with a reduction or absence of blood vessels. This supports the hypothesis that the retrodiscal tissues can behave and function as a joint disc in situations where the position of the true disc is altered.

#### *Disc displacement with reduction*

The joint disc is located anterior, anteromedial or lateral with respect to the condyle. As a result, on starting to open the mouth, the condyle must surpass the posterior margin of the displaced disc, in order to secure a more anterior position. This process is referred to as reduction, an orthopedic term meaning "correction of a fracture, dislocation / luxation, or hernia". Reduction produces a sound (click) as a result of the impact of the condyle against the central (and thinner) portion of the meniscus. Contrarily, on closing the mouth, the condyle undergoes luxation posteriorly with respect to the meniscus, and a sound again can be generated. In this context, when a click is produced both on opening and closing the mouth, the phenomenon is referred to as a reciprocal click. A reciprocal click is usually generated in the more advanced phases of derangement, and the second sound is produced closer to the position of oral closure than the first. In the same way as with the opening click, the further away the closing click is produced from the closed mouth position, the greater the degree of disc dislocation.

The symptoms and signs of disc displacement with reduction can be quite manifest, but are scanty specific of the process. As a result, the variation in diagnostic criteria is very considerable. In their RDC/TMD, Dworkin and LeResche define disc displacement with reduction as displacement of the disc towards an anterior (medial or lateral) position that is reduced in maximum aperture,

generally producing a sound. According to these authors, when accompanied by pain, a complementary diagnostic evaluation of arthritis or arthralgia should be made.

In oblique sagittal projections with the mouth closed, the meniscus is identified - in cases of disc displacement with reduction - as a hypointense band located anterior to the 12 o'clock position with respect to the condyle, and running parallel to the anterior margin of the head of the condyle and anterior aspect of the glenoid cavity and joint eminence.

With the mouth open, the meniscus appears interposed between the joint eminence and the head of the condyle.

#### *Disc displacement without reduction*

In disc displacement with reduction, it is accepted that each time the mouth is opened, the tension generated by the condyle over the posterior band of the meniscus favors elongation of the posterior insertions of the disc in the condyle and glenoid cavity. This gradually causes the condyle to occupy a more anterior position, to the point where the condyle in its displacement does not surpass the posterior margin of the disc. At this point the situation is referred to as disc displacement without reduction.

The signs and symptoms in this case are similar to those of disc displacement with reduction, except that the joint clicks disappear, and a limitation of oral aperture to 25-30 mm (maximum interincisal aperture) may develop.

When disc displacement without reduction is bilateral, the lateralization and protrusion movements are limited. In unilateral presentations deviation is seen towards the affected side at oral aperture, with limitation of canceling of lateralization towards the affected side. In some cases metaplastic phenomena develop in the retrodiscal tissues, which can behave as a pseudodisc - thus allowing patients to recover oral aperture of up to 40-45 mm.

A particular form of disc displacement without reduction is acute block on closing the mouth, defined as the sudden inability to open the mouth. This condition can be caused by other alterations such as muscle spasm or chondromatosis; as a result, antecedents of joint sounds, joint instability or previous blocks reduced by the patient are of great help in establishing the differential diagnosis. In many cases these situations resolve spontaneously.

The signs and symptoms of disc displacement without reduction are in no way specific of the disc disorder. Even imaging technique identification of internal derangement does not necessarily imply that the patient symptoms are caused by it. However, in the case of a patient with chronic and progressive limitation of oral aperture preceded by one or more episodes of acute block, the first suspected diagnosis should be disc displacement without reduction.

### **Osteoarthritis / osteoarthrosis**

According to Okeson, osteoarthritis is a destructive process affecting the articular bone surfaces of the condyle, the glenoid space, or both. In this context, it is interpreted

as the response of the body to increased articular loading. Osteoarthritis is often painful, and the symptoms are exacerbated by mandibular movements. It represents active state bone alterations. Joint remodeling can stabilize function and cause the symptoms to disappear, though altered bone morphology persists - a condition known as osteoarthrosis.

The process is referred to as osteoarthrosis or arthrosis, since this is considered to adequately reflect the non-inflammatory nature of the disorder. In this sense, the term arthritis is reserved for inflammatory, infectious, metabolic or traumatic conditions.

The true frequency of the disease is difficult to establish. There is a poor correlation between the radiological characteristics indicative of osteoarthrosis and the corresponding clinical signs and symptoms. Thus, in epidemiological studies, the frequency of crepitants - considered a sign of osteoarthrosis - ranges from 1-24%; the frequency of radiological changes is 14-44%; macroscopic degenerative changes documented at necropsy are seen in 22-38% of cases; and similar values are recorded for microscopic changes (26).

Classically, the disease has been regarded as a degenerative change of the joint cartilage and subchondral bone. Joint loading beyond chondrocyte adaptation capacity to produce matrix causes the degradation phenomena to exceed repair activity - leading to collapse of the joint cartilage and synovial inflammation.

Studies centered on the TMJ have found an increased prevalence in females (up to 6:1 versus males). Even more extreme results have been obtained by Martínez-Blanco et al. (27), with a distribution indicating 93.8% of female cases versus 6.3% males.

The earliest phases of the arthrosis are characterized by hypertrophic repair of the joint tissue, causing the cartilage to appear thicker than normal. This phase can last decades.

Progression of the disease in turn leads to a decrease in proteoglycans, which causes softening and a reduction in the thickness of the joint cartilage. Vertical defects or gaps are produced as a result. This process is referred to as fibrillation. Under these conditions, the cartilage lacks resistance, and joint movements therefore cause destruction and disappearance of the cartilage layer - leaving the underlying bone exposed. In response, the bone undergoes remodeling and hypertrophy.

The appearance of bone in the subchondral region produces sclerosis, which can be demonstrated by radiological examination.

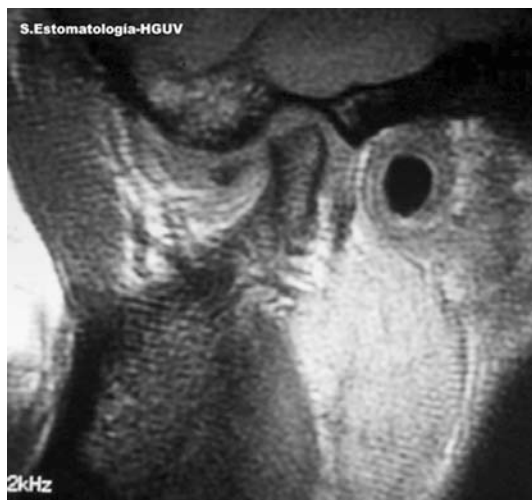Subchondral osteonecrotic phenomena lead to the formation of subchondral bone cysts ("pseudocysts" would be a more apt description), radiologically manifesting as radio-transparent images of variable size, located immediately below the subchondral bone. The onset of the disorder is usually gradual and takes a chronic course. In the great

majority of cases, the symptoms exhibit a "bell-like" distribution, with greater clinical expression in the first 4-7 months, followed by stabilization after 8-9 months, and finally relief or even complete symptoms resolution after 12-18 months. The most common complaints are pain and tenderness (sensitivity) of the joint and masticatory muscles, muscle fatigue, stiffness, difficulty opening the mouth, a diminished range of movements, crepitants, and a roughness sensation in mandibular movements. Pain in response to palpation of the joint capsule (the lateral pole and in part the posterior pole are the only points accessible to palpation) is one of the signs of TMJ osteoarthritis. One of the causes determining joint pain is deterioration of the joint structures; as a result, in those patients without pain, deterioration of the joint surfaces is presumably still in the early phases.

Crepitants generated during joint movements, secondary to cartilage loss and direct friction or rubbing against bone, are one of the diagnostic criteria of osteoarthrosis. Palpation is more effective than auscultation in detecting crepitants; as a result, some authors suggest that auscultation affords little additional information. In contrast, other investigators consider auscultation necessary.

Imaging study of the joints is one of the cornerstones in the diagnosis of osteoarthritis / osteoarthrosis (Fig. 3), though such explorations are also a constant source of controversy regarding problems of sensitivity and specificity. Radiological studies of osteoarthrosis indicate a 40% incidence in patients at around 40 years of age - a figure that practically reaches 100% by 80 years of age. Globally, more than 50% of the general population has changes compatible with osteoarthrosis, though only 30% of these cases become symptomatic at some point in time (28).

Of particular importance for the clinician is prediction of



**Fig. 3.** Condylar leveling and anterior displacement of the disc in a patient with osteoarthritis.

the course of the disease, since this will allow the definition of treatment. An obligate reference in this sense is the work published by Reny de Leeuw et al. in the *Journal of Orofacial Pain* (29), comprising a 30-years retrospective study of osteoarthritis and internal derangement. These authors found that none of the patients had required repeat treatment in the last three decades. Six patients (6%) had suffered signs on the contralateral side, though these required no treatment. The only clinical sign differentiating patients from controls was maximum oral aperture and deviation in protrusion movements - though maximum aperture exceeded 35 mm in 90% of the patients. However, the radiological signs of osteoarthritis were significantly more common in the patients versus the controls.

## References

1. Dworkin SF, LeResche L. Research diagnostic criteria for temporomandibular disorders: review, criteria, examinations and specifications, critique. *J Craniomandib Disord*. 1992 Fall;6(4):301-55.
2. Dworkin SF, LeResche L, DeRouen T, Von Korff M. Assessing clinical signs of temporomandibular disorders: reliability of clinical examiners. *J Prosthet Dent*. 1990 May;63(5):574-9.
3. Anbar M, Gratt BM. The possible role of nitric oxide in the pathophysiology of pain associated with temporomandibular joint disorders. *J Oral Maxillofac Surg*. 1998 Jul;56(7):872-82.
4. Takahashi T, Kondoh T, Kamei K, Seki H, Fukuda M, Nagai H, Takano H, Yamazaki Y. Elevated levels of nitric oxide in synovial fluid from patients with temporomandibular disorders. *Oral Surg Oral Med Oral Pathol Oral Radiol Endod*. 1996 Nov;82(5):505-9.
5. Sandler NA, Buckley MJ, Cillo JE, Braun TW. Correlation of inflammatory cytokines with arthroscopic findings in patients with temporomandibular joint internal derangements. *J Oral Maxillofac Surg*. 1998 May;56(5):534-43; discussion 543-4.
6. Durante W, Liao L, Iftikhar I, O'Brien WE, Schafer AI. Differential regulation of L-arginine transport and nitric oxide production by vascular smooth muscle and endothelium. *Circ Res*. 1996 Jun;78(6):1075-82.
7. Sandler NA, Macmillan C, Buckley MJ, Barnes L. Histologic and histochemical changes in failed auricular cartilage grafts used for a temporomandibular joint disc replacement: a report of three cases and review of the literature. *J Oral Maxillofac Surg*. 1997 Sep;55(9):1014-9.
8. Toyama M, Kurita K, Koga K, Ogi N. Ankylosis of the temporomandibular joint developing shortly after multiple facial fractures. *Int J Oral Maxillofac Surg*. 2003 Aug;32(4):360-2.
9. del Palomar AP, Doblare M. 3D finite element simulation of the opening movement of the mandible in healthy and pathologic situations. *J Biomech Eng*. 2006 Apr;128(2):242-9.
10. Gallo LM, Airoidi R, Ernst B, Palla S. Power spectral analysis of temporomandibular joint sounds in asymptomatic subjects. *J Dent Res*. 1993 May;72(5):871-5.
11. Crow HC, Parks E, Campbell JH, Stucki DS, Daggy J. The utility of panoramic radiography in temporomandibular joint assessment. *Dentomaxillofac Radiol*. 2005 Mar;34(2):91-5.
12. Magnusson T, Karlsson C. Clinical impact of radiological examinations of patients with suspected temporomandibular disorders. *Swed Dent J*. 2002;26(2):67-74.
13. Epstein JB, Caldwell J, Black G. The utility of panoramic imaging of the temporomandibular joint in patients with temporomandibular disorders. *Oral Surg Oral Med Oral Pathol Oral Radiol Endod*. 2001 Aug;92(2):236-9.
14. Hayashi T, Ito J, Koyama J, Hinoki A, Kobayashi F, Torikai Y, et al. Detectability of anterior displacement of the articular disk in the temporomandibular joint on helical computed tomography: the value of open mouth position. *Oral Surg Oral Med Oral Pathol Oral Radiol Endod*. 1999 Jul;88(1):106-11.
15. Huddleston Slater JJ, Lobbezoo F, Hofman N, Naeije M. Case report of a posterior disc displacement without and with reduction. *J Orofac Pain*. 2005 Fall;19(4):337-42.
16. Suenaga S, Abeyama K, Hamasaki A, Mimura T, Noikura T. Temporomandibular disorders: relationship between joint pain and effusion and nitric oxide concentration in the joint fluid. *Dentomaxillofac Radiol*. 2001 Jul;30(4):214-8.
17. Guler N, Uckan S, Imirzalioglu P, Acikgozdoglu S. Temporomandibular joint internal derangement: relationship between joint pain and MR grading of effusion and total protein concentration in the joint fluid. *Dentomaxillofac Radiol*. 2005 May;34(3):175-81. PMID: 15897289
18. Sener S, Akganlu F. MRI characteristics of anterior disc displacement with and without reduction. *Dentomaxillofac Radiol*. 2004 Jul;33(4):245-52.
19. Manfredini D, Tognini F, Zampa V, Bosco M. Predictive value of clinical findings for temporomandibular joint effusion. *Oral Surg Oral Med Oral Pathol Oral Radiol Endod*. 2003 Nov;96(5):521-6. 20. Kaneyama K, Segami N, Nishimura M, Suzuki T, Sato J. Importance of proinflammatory cytokines in synovial fluid from 121 joints with temporomandibular disorders. *Br J Oral Maxillofac Surg*. 2002 Oct;40(5):418-23.
21. Chang H, Israel H. Analysis of inflammatory mediators in temporomandibular joint synovial fluid lavage samples of symptomatic patients and asymptomatic controls. *J Oral Maxillofac Surg*. 2005 Jun;63(6):761-5.
22. Arinci A, Ademoglu E, Aslan A, Mutlu-Turkoglu U, Karabulut AB, Karan A. Molecular correlates of temporomandibular joint disease. *Oral Surg Oral Med Oral Pathol Oral Radiol Endod*. 2005 Jun;99(6):666-70.
23. Suzuki T, Segami N, Nishimura M, Sato J, Nojima T. Bradykinin expression in synovial tissues and synovial fluids obtained from patients with internal derangement of the temporomandibular joint. *Cranio*. 2003 Oct;21(4):265-70.
24. Nitzan DW. The process of lubrication impairment and its involvement in temporomandibular joint disc displacement: a theoretical concept. *J Oral Maxillofac Surg*. 2001 Jan;59(1):36-45. PMID: 11152188
25. Scapino RP. Histopathology associated with malposition of the human temporomandibular joint disc. *Oral Surg Oral Med Oral Pathol*. 1983 Apr;55(4):382-97.
26. Axelsson S. Human and experimental osteoarthritis of the temporomandibular joint. Morphological and biochemical studies. *Swed Dent J Suppl*. 1993;92:1-45.
27. Martinez Blanco M, Bagan JV, Fons A, Poveda Roda R. Osteoarthritis of the temporomandibular joint. A clinical and radiological study of 16 patients. *Med Oral*. 2004 Mar-Apr;9(2):110-15, 106-10.
28. Wiberg B, Wanman A. Signs of osteoarthritis of the temporomandibular joints in young patients: a clinical and radiographic study. *Oral Surg Oral Med Oral Pathol Oral Radiol Endod*. 1998 Aug;86(2):158-64.
29. de Leeuw R, Boering G, Stegenga B, de Bont LG. Clinical signs of TMJ osteoarthritis and internal derangement 30 years after nonsurgical treatment. *J Orofac Pain*. 1994 Winter;8(1):18-24.