

Regional odontodysplasia of the deciduous and permanent teeth associated with eruption disorders: A case report

Kaan Gündüz ¹, Zeynep Zengin ², Peruze Çelenk ³, Bora Özden ⁴, Murat Kurt ⁵, Omer Gunhan ⁶

- (1) Assistant Professor. Ondokuz Mayıs University Faculty of Dentistry. Department of Oral Diagnosis and Radiology, Samsun
 (2) Research Assistant. Ondokuz Mayıs University Faculty of Dentistry. Department of Oral Diagnosis and Radiology, Samsun
 (3) Professor. Ondokuz Mayıs University Faculty of Dentistry. Department of Oral Diagnosis and Radiology, Samsun
 (4) Assistant Professor. Ondokuz Mayıs University Faculty of Dentistry. Department of Oral and Maxillofacial Surgery, Samsun
 (5) Assistant Professor. Ondokuz Mayıs University Faculty of Dentistry. Department of Prosthodontics, Samsun
 (6) Professor. Gulhane Military Medical Academy, Department of Oral Pathology

Correspondence:

Dr. Kaan Gündüz

Ondokuz Mayıs University

Faculty of Dentistry

Department of Oral Diagnosis and Radiology

55139 Kurupelit Samsun Turkey

E-mail : kgunduz@omu.edu.tr

Received: 19/11/2007

Accepted: 02/04/2008

Indexed in:

-Index Medicus / MEDLINE / PubMed
 -EMBASE, Excerpta Medica
 -SCOPUS
 -Índice Médico Español
 -IBCS

Gündüz K, Zengin Z, Çelenk P, Özden B, Kurt M, Gunhan O. Regional odontodysplasia of the deciduous and permanent teeth associated with eruption disorders: A case report. Med Oral Patol Oral Cir Bucal. 2008 Sep1;13(9):E563-6.

© Medicina Oral S. L. C.I.F. B 96689336 - ISSN 1698-6946

<http://www.medicinaoral.com/medoralfree01/v13i9/medoralv13i9p563.pdf>

Abstract

Regional odontodysplasia (RO) is an unusual, non-hereditary anomaly of the dental hard tissues with characteristic clinical, radiographic and histological findings. Clinically, RO affects the primary and permanent dentition in the maxilla and mandible or both jaws. Radiographically, there is a lack of contrast between the enamel dentin, both of which are less radiopaque than unaffected counterparts. Additionally, enamel and dentin layers are thin, giving the teeth a “ghost-like” appearance. Histologically, areas of hypocalcified enamel are visible and enamel prisms appear irregular in direction. Coronal dentin is fibrous, consisting of clefts and a reduced number of dentinal tubules; radiolar dentin is generally more normal in structure and calcification.

The RO etiology is uncertain; numerous factors have been suggested and considered as local trauma, irradiation, hypophosphatasia, hypocalcemia, hyperpyrexia. The treatment of RO has given rise to controversy. These cases require a continuous and multidisciplinary approach. Most clinicians advocate extracting the affected teeth as soon as possible and inserting a prosthetic replacement. Other clinicians prefer restorative procedures, if possible, to protect the affected erupted teeth.

A case of RO in an 8 year-old male whose chief complaint was the absence of eruption of permanent teeth is presented. Clinical, radiographic and histological findings are described.

Key words: Regional odontodysplasia, ghost teeth.

Introduction

Regional odontodysplasia (RO) is a rare, nonhereditary developmental anomaly affecting dental tissues derived from both the mesoderm and ectoderm (1,2).

The first report of this condition was published by McCall and Wald (3) in 1947, but the term ‘odontodysplasia’ was introduced by Zegarelli et al (4), in 1963. Since that time, a number of cases have been described under a variety of names; such as localized arrested tooth development, regional odontodysplasia, ghost teeth, odontogenesis

imperfecta, unilateral dental malformation, amelogenesis imperfecta non-hereditary segmentalis and familial amelodontal dysplasia (5).

The criteria for RO diagnosis are based on clinical, radiographic, and histologic findings. Clinically, RO can affect the primary and permanent dentition in either the maxilla, the mandible or both together(6,7). Though the condition most often affects only one quadrant, cases with bilateral or multi-quadrant involvement have also been reported (6). The maxillary teeth are affected more

frequently than the mandibular, the maxillary central and lateral incisors and canines being more affected than the posterior teeth (8-10).

When RO is observed in the primary dentition, teeth can be erupted, hypoplastic, hypocalcified, with changes in color and form (11). Affected teeth are likely to be small, brown, grooved, and hypoplastic (12). Gingival tissue can be hyperemic and usually presents a fistula. In the permanent dentition, teeth usually are not erupted or can be partially erupted with fibrous gingival tissue and swelling (8).

Radiographically, there is a lack of contrast between the enamel dentin, both of which are less radiopaque than unaffected counterparts. Additionally, enamel and dentin layers are thin, giving the teeth a 'ghost-like' appearance (5-9,13). The pulp chambers are noticeably enlarged with open apices and enlarged follicles.

Histologically, areas of hypocalcified enamel are visible and enamel prisms appear irregular in direction (14). Coronal dentin is fibrous, consisting of clefts and a reduced number of dentinal tubules; radicular dentin is generally more normal in structure and calcification (15). Pulpal calcification of various degrees is also commonly seen (2). The mineral content of the affected enamel has been found to be higher than that of dentin in microradiographic studies. The greater density of the enamel is not evident in conventional radiographs, probably because of the thinness of the enamel layer in affected teeth (15).

This paper reports a case of regional odontodysplasia of the deciduous and permanent teeth associated with eruption disorders.

Case Report

A 8-year-old healthy Turkish boy, was referred due to the absence of eruption of permanent teeth. His prenatal, birth, medical and family history were unremarkable. According to his mother, the anterior right deciduous teeth had been different from the others and a yellowish color. They had become quickly destroyed by carious processes.

Clinically, the deciduous canine tooth on the right maxilla was yellowish-brown in color. It was smaller than normal with rough, irregular surfaces, and exposed pulp due to caries or fracture (Figure 1). All other primary teeth on the other quadrants were normally formed with carious processes on approximal surfaces. The maxillary right permanent central tooth was not erupted with no sign of gingival swelling or abscess formation.

Radiographically, the maxillary right deciduous canine tooth and germs of the maxillary right permanent central, lateral and canine teeth were all reduced in radiodensity in comparison to the unaffected teeth. All the primary teeth and the germs of the permanent teeth in other quadrants were normal (Figure 2).

The periapical radiographs of the affected teeth demonstrated very thin dentin and enamel layers. The demarcation

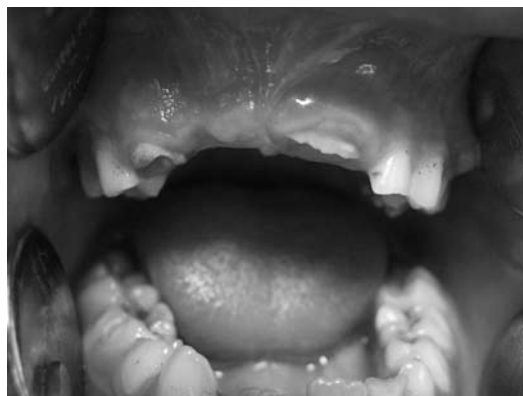

Fig. 1. Intraoral view of upper right area with regional odontodysplasia.

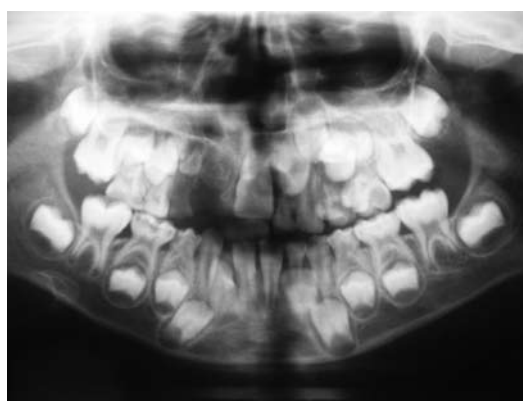


Fig. 2. Panoramic radiograph shows the teeth with 'ghost-like' appearance in maxillary right quadrant. All teeth are normal except in the right maxillary quadrant.

between them was not observed and pulp chambers were wide, all of which gave rise to a 'ghost-like' appearance (Figure 3). In affected permanent teeth, root formation was immature and the roots were aplastic. Dental development from radiographs appeared age-appropriate and showed normal thickness of enamel and dentin in primary and permanent dentitions in the other quadrants.

The treatment suggested to the patient's mother was the extraction of the maxillary right permanent central tooth. The affected maxillary right deciduous canine tooth was also extracted. The specimen, consisting of teeth fragments, was sent to oral pathology for a histopathology report that confirmed the clinical diagnosis of RO. Histological examination of the removed teeth showed irregular dentin with areas of interglobular dentin and the presence of immature odontogenic epithelium in the connective tissue. (Figure 4)

The affected edentulous quadrant was also rehabilitated with temporary acrylic maxillary partial denture (Figure 5). The patient was placed on periodic recall to observe the progress of eruption of the maxillary right permanent lateral and canine tooth and to monitor the growth and development of maxillary and mandibular dental arches.

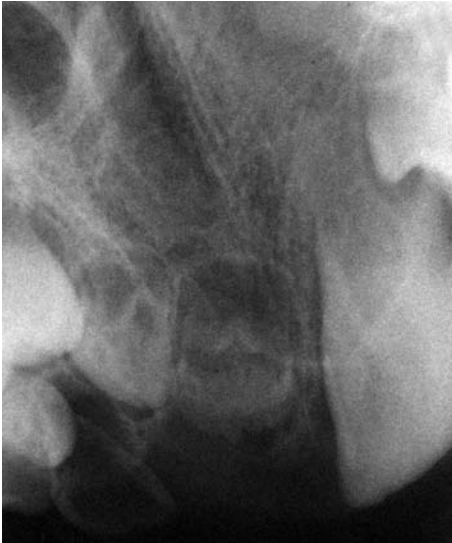

Fig. 3. Periapical radiograph showing the characteristically ghost-like appearance of regional odontodysplasia.

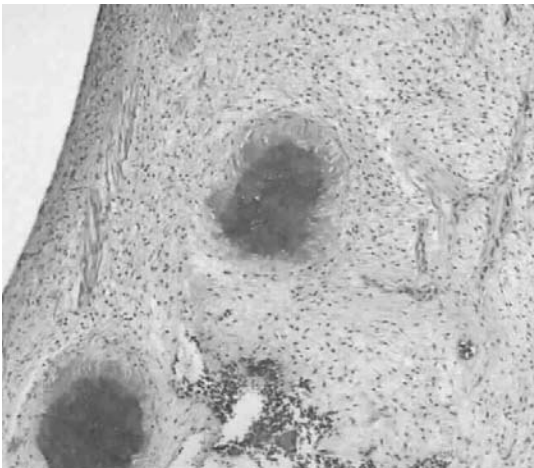


Fig. 4. Histological examination shows irregular dentin with areas of interglobular dentin and the presence of immature odontogenic epithelium in the connective tissue.(HEx200).

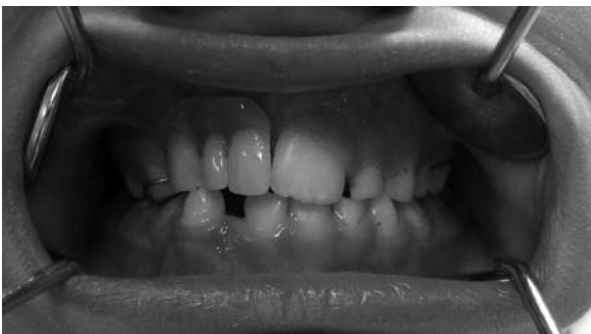

Fig. 5. The affected edentulous quadrant was rehabilitated with an acrylic partial denture.

Discussion

RO is a relatively rare, localized developmental anomaly that affects both the dentin and enamel of a group of contiguous teeth. It occurs in both deciduous and permanent dentition, but has a marked preference for the maxilla (6). The RO etiology is uncertain; numerous factors have been suggested and considered as local trauma, irradiation, hypophosphatasia, hypocalcemia, hyperpyrexia (2,4,7). The RO has also been related to the activation of latent viruses in the odontogenic epithelium, to the presence of nevus, hemangiomas and hydrocephaly, but most of the cases present no relevant information (10,16-18). However, it is noteworthy that the patient described here did not present with any of these conditions. In conclusion, the cause of the present case seems to be unknown.

Conditions which show some similarities to RO include amelogenesis imperfecta, dentinogenesis imperfecta, dentinal dysplasia types I and II, shell teeth, and hypophosphatasia (19,20). All these anomalies, tend to affect the entire dentition instead of showing segmental distribution. Radiographically, unerupted teeth affected by RO may be incorrectly diagnosed as undergoing root resorption or being an odontoma (21).

The patient in this report exhibits several aspects of the common clinical, radiographic and histopathologic features related to regional odontodysplasia. However, some of these important features are absent. According to the literature, abscess formation is the main reason for extraction of affected teeth, but absence of eruption of permanent teeth was the chief complaint of our patient. There was no sign of gingival swelling or abscess formation. Additionally, the patient is a male whereas according to the literature this condition seems to be more prevalent in females. Therefore, further studies with a greater number of cases are necessary to confirm this tendency.

The treatment of RO has given rise to controversy. These cases require a continuous and multidisciplinary approach. Most clinicians advocate extracting the affected teeth as soon as possible and inserting a prosthetic replacement (6-9,17). Other clinicians prefer restorative procedures, if possible, to protect the affected erupted teeth (12,16). However, selection of method and timing appear to be critical factors in the treatment of RO. Although in very young children teeth in the arch should be retained, teeth involved with abscesses can not be restored, and need to be extracted (17). In contrast, in older children, abscessed permanent teeth should be extracted with others retained until final rehabilitation with implants and/or fixed prosthesis (19).

Taking these goals into consideration, we examined the affected teeth clinically and radiographically and decided to extract the maxillary right permanent central, and deciduous canine teeth. The affected maxillary right permanent lateral and canine teeth were not extracted to observe the progress of eruption. The edentulous quadrant was

rehabilitated with a partial denture. The patient was placed on periodic recall to monitor the growth and development of maxillary and mandibular dental arches.

References

1. Gibbard PD, Lee KW, Winter GB. Odontodysplasia. *Br Dent J*. 1973 Dec 18;135(12):525-32.
2. Gardner DG, Sapp JP. Ultrastructural, electron-probe, and microhardness studies of the controversial amorphous areas in the dentin of regional odontodysplasia. *Oral Surg Oral Med Oral Pathol*. 1977 Oct;44(4):549-59.
3. McCall JO, Wald SS. *Clinical dental roentgenology*. 3rd ed. Philadelphia: WB Saunders; 1952. p. 170.
4. Zegarelli EV, Kutscher AH, Applebaum E, Archard HO. Odontodysplasia. *Oral Surg Oral Med Oral Pathol*. 1963 Feb;16:187-93.
5. Pandis N, Polido C, Bell WH. Regional odontodysplasia. A case associated with asymmetric maxillary and mandibular development. *Oral Surg Oral Med Oral Pathol*. 1991 Oct;72(4):492-6.
6. Lustmann J, Klein H, Ulmanský M. Odontodysplasia. Report of two cases and review of the literature. *Oral Surg Oral Med Oral Pathol*. 1975 May;39(5):781-93.
7. Ozer L, Cetiner S, Ersoy E. Regional odontodysplasia: report of a case. *J Clin Pediatr Dent*. 2004 Fall;29(1):45-8.
8. Vaikuntam J, Tatum NB, McGuff HS. Regional odontodysplasia: review of the literature and report of a case. *J Clin Pediatr Dent*. 1996 Fall;21(1):35-40.
9. Sabah E, Eden E, Unal T. Odontodysplasia: report of a case. *J Clin Pediatr Dent*. 1992 Winter;16(2):115-8.
10. Steiman HR, Cullen CL, Geist JR. Bilateral mandibular regional odontodysplasia with vascular nevus. *Pediatr Dent*. 1991 Sep-Oct;13(5):303-6.
11. Crawford PJ, Aldred MJ. Regional odontodysplasia: a bibliography. *J Oral Pathol Med*. 1989 May;18(5):251-63.
12. Yuan SH, Liu PR, Childers NK. An alternative restorative method for regional odontodysplasia: case report. *Pediatr Dent*. 1997 Sep-Oct;19(6):421-4.
13. Rushton MA. Odontodysplasia: "Ghost Teeth". *Br Dent J*. 1965 Aug 3;119:109-13.
14. Herold RC, Lally ET, Gold L. Abnormal tooth tissue in human odontodysplasia. *Oral Surg Oral Med Oral Pathol*. 1976 Sep;42(3):357-65.
15. Rohanizadeh R, Použat J, Bohne W, Ajacques JC. Ultrastructural organization and microanalysis studies of deciduous enamel crystallites in regional odontodysplasia (RO). *J Oral Pathol Med*. 1998 Nov;27(10):501-7.
16. Oncag O, Eronat C, Sen BH. Regional odontodysplasia: a case report. *J Clin Pediatr Dent*. 1996 Fall;21(1):41-6.
17. Cabral LA, Carvalho YR, Moraes E, Nogueira Tde O, Cavalcante AS, De Moraes LC. Regional odontodysplasia: a report of three cases. *Quintessence Int*. 1994 Feb;25(2):141-5.
18. Kahn MA, Hinson RL. Regional odontodysplasia. Case report with etiologic and treatment considerations. *Oral Surg Oral Med Oral Pathol*. 1991 Oct;72(4):462-7.
19. Llana-Puy MC, Forner-Navarro L. An unusual morphological anomaly in an incisor crown. Anterior dens evaginatus. *Med Oral Patol Oral Cir Bucal*. 2005 Jan-Feb;10(1):15-6; 13-5.
20. Sánchez-Quevedo C, Ceballos G, Rodríguez IA, García JM, Alaminos M. Acid-etching effects in hypomineralized amelogenesis imperfecta. A microscopic and microanalytical study. *Med Oral Patol Oral Cir Bucal*. 2006 Jan 1;11(1):E40-3.
21. Amado Cuesta S, Gargallo Albiol J, Berini Aytés L, Gay Escoda C. Review of 61 cases of odontoma. Presentation of an erupted complex odontoma. *Med Oral*. 2003 Nov-Dec;8(5):366-73.