

Treatment of bilateral hyperplasia of the coronoid process of the mandible. Presentation of a case and review of the literature

Martín Fernández Ferro ¹, Jacinto Fernández Sanromán ², Jesús Sandoval Gutierrez ¹, Alberto Costas López ¹, Annahys López de Sánchez ¹, Amaya Etayo Pérez ¹

(1) Médico Adjunto

(2) Jefe de Servicio. Servicio de Cirugía Oral y Maxilofacial, Hospital Povisa. Vigo

Correspondence:

Dr. Martín Fernández Ferro

Servicio de Cirugía Oral y Maxilofacial

Hospital Povisa.

C/ Salamanca 5, 36211. Vigo, Spain

E-mail: martinferro@yahoo.es

Received: 02/01/2008

Accepted: 27/04/2008

Indexed in:

-Index Medicus / MEDLINE / PubMed
-EMBASE, Excerpta Medica
-SCOPUS
-Índice Médico Español
-IBCS

Fernández-Ferro M, Fernández-Sanromán J, Sandoval-Gutierrez J, Costas-López A, López-de Sánchez A, Etayo-Pérez A. Treatment of bilateral hyperplasia of the coronoid process of the mandible. Presentation of a case and review of the literature. Med Oral Patol Oral Cir Bucal. 2008 Sep1;13(9):E595-8.

© Medicina Oral S. L. C.I.F. B 96689336 - ISSN 1698-6946

<http://www.medicinaoral.com/medoralfree01/v13i9/medoralv13i9p595.pdf>

Abstract

Bilateral hyperplasia of the coronoid process is infrequent. It consists of an elongation of the coronoid process of the mandible and is, accordingly, a mechanical problem, limiting mouth opening. This article looks at the case of a 28 year-old male with significant limitation on opening his mouth, secondary to bilateral hyperplasia of the coronoid process. We reviewed the literature and analysed the diagnostic and therapeutic procedures used, paying special attention to the surgical approaches to the coronoid process and emphasising the importance of early post-operative rehabilitation, describing our experience with the TheraBite® (Atos Medical AB, PO Box 183, 242 22 Hörby, Sweden). The satisfactory result of the procedure is marked by the stable recovery of the mouth opening, achieved by a good combination of surgical and physiotherapeutic techniques.

Key words: *Hyperplasia, coronoidectomy, physiotherapy, coronoid process.*

Introduction

Bilateral hyperplasia of the coronoid process of the mandible is defined as an abnormal elongation of the coronoid process, formed of histologically normal bone. The main clinical finding is a progressive, painless difficulty in opening the mouth, due to contact with the temporal surface of the zygomatic bone or medial surface of the zygomatic arch (1). Though unusual in clinical practice, it has been well described in the literature and in specialised books. We discuss here a new clinical case of a 28 year-old male diagnosed with bilateral hyperplasia of the coronoid process evolving over a long period. The patient underwent a bilateral intraoral coronoidectomy, followed by rehabilitation, for which we recommended the use of the TheraBite® (registered trademark of Atos Medical AB, Sweden, distributed in Spain by Tarma S.A.). This is an easy-to-use active and passive physiotherapy implement, which has proven efficacious at achieving and maintain-

ing the right mouth opening (2). This paper describes the surgical and rehabilitation treatment, placing special emphasis on the importance of a physiotherapy protocol leading to stable, satisfactory results.

Case history

28 year-old male with no medical history of interest, referred to us by his dentist, to evaluate a trismus evolving over a long period. The patient mentioned asymptomatic difficulty in opening his mouth, over an unspecified number of years. On examination, he was found to have an interincisal opening of 13 mm, with limited lateral and protrusive jaw movements. No hypertrophy of the masseter muscles was found and the patient has no history of pain and/or dysfunction of the temporomandibular joint.

A cephalometric examination showed Class III Angle malocclusion with a right crossbite. Orthopantomography showed an elongation of the coronoid process, and accor-

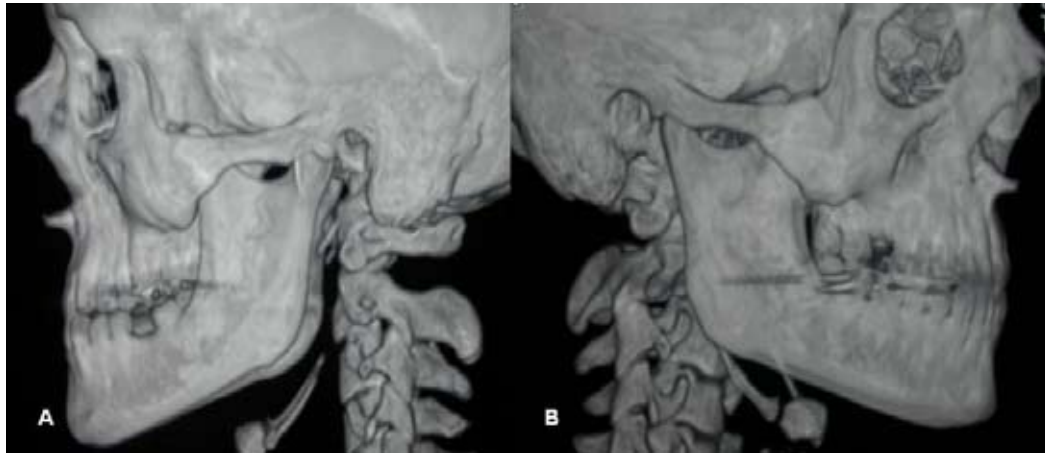


Fig. 1. A and B) 3D-CT image of left and right coronoid process hyperplasia.

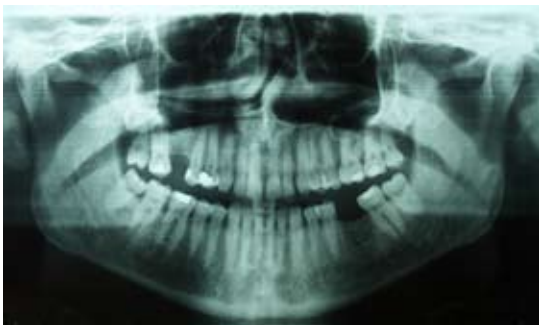


Fig. 2. Orthopantomography showing bilateral hyperplasia of the coronoid process, used as a pre-operative control.

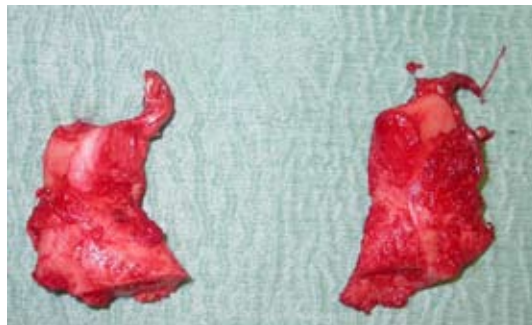

Fig. 3. Close-up of the coronoid process after coronoidectomy.

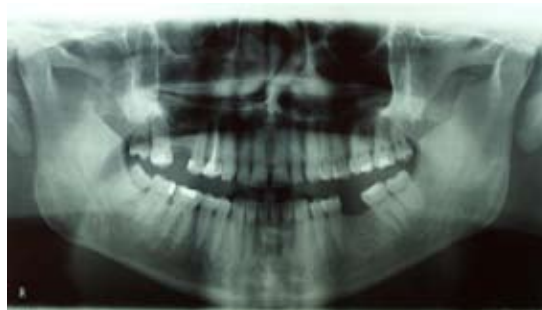


Fig. 4. Post-operative orthopantomography.

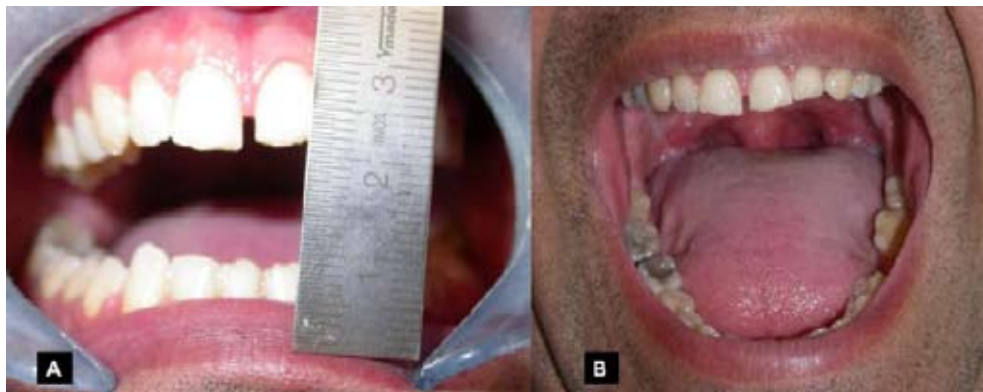

Fig. 5. A) Mouth opening prior to operation. B) Mouth opening after operation.

dingly a CT scan was carried out with three-dimensional reconstruction (3D CT), showing bilateral hyperplasia of the coronoid process and contact between said process and the zygomatic arch, limiting mouth opening movement. An intraoral bilateral coronoidectomy was carried out under general anaesthesia, the anatomic-pathological study confirming that the bone was histologically normal. Post-operative period without incident. One week after surgery, rehabilitation was begun using a TheraBite® 3-5 times a day for 10 minutes, over a period of three months. A mouth opening of 40 mm was obtained, remaining stable at successive revisions after one month, three months, six months and one year with no recidivism in the coronoid process growth or decrease in the mouth opening (Figs. 1-5).

Discussion

Elongation of the coronoid process of the mandible was described for the first time in 1853 by Von Langenbeck (3). In 1899, Jacob (4) described a synovial joint formation between an elongated coronoid process and the homolateral zygomatic bone.

Since then several cases have been described, creating a certain confusion between hyperplasia of the coronoid process, Jacob's disease and even lesions such as osteoma and osteochondroma, which may also cause elongation of the coronoid process (5-7). The case discussed here would best be described simply as hyperplasia of the coronoid process, an elongation of histologically normal bone with no synovial tissue. Unilateral and bilateral cases have been described, in both men and women, at a ratio of 5:1, although bilateral cases are more frequent in men. The median age is 25 (1).

The aetiology of the complaint is unknown, although several theories have been postulated, including hyperactivity of the temporal muscle, causing reactive elongation of the coronoid process (8), dysfunction of the temporomandibular joint caused by chronic disc displacement, which would be related with cases of unilateral hyperplasia and is mentioned as one of the causes of Jacob's disease (9, 10), endocrine stimuli (11), traumatism (12) and even genetic and family factors (13). The literature establishes no relationship between a specific cephalometric pattern and coronoid hyperplasia.

In addition to painless and progressive limitation of the mouth opening, possibly evolving over years, the disorder can be diagnosed by means of radiology: an initial orthopantomography and, if the suspicion persists, 3D CT, which will give an exact indication of the length of the coronoid process and its situation in relation to the zygomatic bone and/or arch (14).

The main aim of treatment is to restore the mouth opening, in a stable manner. As the problem is essentially a mechanical one, most authors (up to 90% of all cases) (1, 15) agree on intraoral coronoidectomy as the treatment

of choice. This gives access to the coronoid process, decreases morbidity to the facial nerve and avoids unsightly scarring. Other authors use the submandibular approach in case of zygomatic-coronoid ankylosis (16), and the coronal approach has also been described in cases of very elongated coronoid processes or associated lesions, such as osteochondroma (5, 17). It can be difficult to establish the best time to administer treatment in infants or pre-adolescents, although most authors agree that, except in patients with very severe limitation of the mouth opening (18, 19), it is best to perform the operation once the growth process has finished, in order to avoid recurrence, deformity or even restricted movement.

Obtaining a satisfactory outcome will depend largely on proper post-operative rehabilitation. Cases of limitation of mouth opening caused by fibrosis, secondary to incorrect reorganisation of a haematoma in the operated area (1, 2) and even recurrence in the growth of the coronoid process (20) have been described.

In a review of 31 cases, McLoughlin et al. (1) describes how only half of patients treated can open their mouths more than 30 mm, and suggests inadequate rehabilitation as a possible cause of this failure. Accordingly, the importance of early post-operative physiotherapy is emphasised by many authors (5, 10, 15), although most of them do not describe the protocols used.

Many instruments, such as spatulas, wedges or tweezers, are habitually used in mouth opening exercises. However, these normally have the wrong type of surface, and exert greater pressure on the incisors, with the consequent danger of causing dislocation or fractures of the teeth.

Accordingly, we propose our rehabilitation protocol, in which we recommend the use of the TheraBite®, a simple manual physiotherapy device, with two padded, horseshoe-shaped contact surfaces, which distribute the stress evenly over the 10 front teeth of each jaw, exerting less pressure on the incisors and decreasing the risk of damage to the teeth. The action works through a combination of stretching and passive movements, increasing mandibular opening and mobility and avoiding overloading the joint. The main indication is to improve the mouth opening in cases of restricted mobility secondary to soft tissue fibrosis after surgical treatment to the head and neck (2). We recommend that physiotherapy begin between three days and one week after surgery, the exercises to be performed for 10 minutes three times daily and repeated over 3-6 months.

In short, successful treatment of bilateral hyperplasia of the coronoid process depends on the one hand on the right surgical technique, for which the correct approach needs to be established in each case, and, on the other, on early post-operative physiotherapy, for which we recommend, for its advantages over other appliances, the TheraBite®, to be used constantly over 3-6 months.

References

1. McLoughlin PM, Hopper C, Bowley NB. Hyperplasia of the mandibular coronoid process: an analysis of 31 cases and a review of the literature. *J Oral Maxillofac Surg.* 1995 Mar;53(3):250-5.
2. Gibbons AJ, Abulhoul S. Use of a Therabite appliance in the management of bilateral mandibular coronoid hyperplasia. *Br J Oral Maxillofac Surg.* 2007 Sep;45(6):505-6.
3. Von Langenbeck B. Angeborene Kleinheit der unteren Kiefer. *Langenbeck's Archiv.* 1861; 1: 451-5.
4. Jacob O. Une cause rare de constriction permanente des mâchoires. *Bull et Mem de la Société Anatomique de Paris.* 1899 ; 1 : 917-2.
5. Hernández-Alfaro F, Escuder O, Marco V. Joint formation between an osteochondroma of the coronoid process and the zygomatic arch (Jacob disease): report of case and review of literature. *J Oral Maxillofac Surg.* 2000 Feb;58(2):227-32.
6. Escuder i de la Torre O, Vert Klok E, Mari i Roig A, Mommaerts MY, Pericot i Ayats J. Jacob's disease: report of two cases and review of the literature. *J Craniomaxillofac Surg.* 2001 Dec;29(6):372-6.
7. Villanueva J, González A, Cornejo M, Núñez C, Encina S. Osteochondroma of the coronoid process. *Med Oral Patol Oral Cir Bucal.* 2006 May 1;11(3):E289-91.
8. Lyon LZ, Sarnat BG. Limited opening of the mouth caused by enlarged coronoid processes: report of case. *J Am Dent Assoc.* 1963 Nov;67:644-50.
9. Capote A, Rodríguez FJ, Blasco A, Muñoz MF. Jacob's disease associated with temporomandibular joint dysfunction: a case report. *Med Oral Patol Oral Cir Bucal.* 2005 May-Jul;10(3):210-4.
10. Isberg A, Isacson G, Nah KS. Mandibular coronoid process locking: a prospective study of frequency and association with internal derangement of the temporomandibular joint. *Oral Surg Oral Med Oral Pathol.* 1987 Mar;63(3):275-9.
11. Rowe NL. Bilateral developmental hyperplasia of the mandibular coronoid process: a report of two cases. *Br J Oral Surg.* 1963 Nov;1:90-104.
12. Tucker MR, Guilford WB, Howard CW. Coronoid process hyperplasia causing restricted opening and facial asymmetry. *Oral Surg Oral Med Oral Pathol.* 1984 Aug;58(2):130-2.
13. York BV, Cockerham S. Bilateral hyperplasia of the coronoid processes in siblings. *Oral Surg Oral Med Oral Pathol.* 1983 Dec;56(6):584-5.
14. Takahashi A, Hao-Zong W, Murakami S, Kondoh H, Fujishita M, Fuchihata H. Diagnosis of coronoid process hyperplasia by three-dimensional computed tomographic imaging. *Dentomaxillofac Radiol.* 1993 Aug;22(3):149-54.
15. Gerbino G, Bianchi SD, Bernardi M, Berrone S. Hyperplasia of the mandibular coronoid process: long-term follow-up after coronoidotomy. *J Craniomaxillofac Surg.* 1997 Jun;25(3):169-73.
16. Ostrofsky MK, Lownie JF. Zygomatico-coronoid ankylosis. *J Oral Surg.* 1977 Sep;35(9):752-4.
17. Hayter JP, Robertson JM. Surgical access to bilateral coronoid hyperplasia using the bicoronal flap. *Br J Oral Maxillofac Surg.* 1989 Dec;27(6):487-93.
18. Mano T, Ueyama Y, Koyama T, Nishiyama A, Matsumura T. Trismus due to bilateral coronoid hyperplasia in a child: case report. *J Oral Maxillofac Surg.* 2005 Mar;63(3):399-401.
19. Satoh K, Ohno S, Aizawa T, Imamura M, Mizutani H. Bilateral coronoid hyperplasia in an adolescent: report of a case and review of the literature. *J Oral Maxillofac Surg.* 2006 Feb;64(2):334-8.
20. Smyth AG, Wake MJ. Recurrent bilateral coronoid hyperplasia: an unusual case. *Br J Oral Maxillofac Surg.* 1994 Apr;32(2):100-4.