

Journal section: Oral Surgery
 Publication Types: Review

doi:10.4317/medoral.21698
<http://dx.doi.org/doi:10.4317/medoral.21698>

Periapical implant lesion: A systematic review

Juan-Antonio Blaya-Tárraga ¹, Juan Cervera-Ballester ², David Peñarrocha-Oltra ³, Miguel Peñarrocha-Diago ⁴

¹ DDS, MSc. Master of Oral Surgery and Implantology. University of Valencia Medical and Dental School. Valencia, Spain

² DDS, MSc. Collaborator Professor Oral Surgery. University of Valencia Medical and Dental School, Spain

³ DDS, MSc, PhD. Assistant Professor Oral Surgery. University of Valencia Medical and Dental School, Spain

⁴ MD, MDM, PhD. Chairman of Oral Surgery, Director of Master in Oral Surgery and Implantology. University of Valencia Medical and Dental School, Spain

Correspondence:

Unidad de Cirugía Bucal
 Facultat de Medicina i Odontologia
 Universitat de València
 C/ Gascó Oliag 1
 46010 Valencia, Spain
miguel.penarrocha@uv.es

Blaya-Tárraga, JA, Cervera-Ballester, J, Peñarrocha-Oltra D, Peñarrocha-Diago M. Periapical implant lesion: a systematic review. Med Oral Patol Oral Cir Bucal. Med Oral Patol Oral Cir Bucal. 2017 Nov 1;22 (6):e737-49.

<http://www.medicinaoral.com/medoralfree01/v22i6/medoralv22i6p737.pdf>

Received: 26/10/2016
 Accepted: 03/05/2017

Article Number: 21698 <http://www.medicinaoral.com/>
 © Medicina Oral S. L. C.I.F. B 96689336 - pISSN 1698-4447 - eISSN: 1698-6946
 eMail: medicina@medicinaoral.com
Indexed in:
 Science Citation Index Expanded
 Journal Citation Reports
 Index Medicus, MEDLINE, PubMed
 Scopus, Embase and Emcare
 Índice Médico Español

Abstract

Purpose: The aim of this study was to systematically review the evidence for periapical implant lesion, which makes a patient more susceptible to the periapical lesion, frequency, symptoms, signs (including radiological findings) and possible treatment options.

Material and Methods: A systematic literature review and analysis of publications included in PubMed, Embase and Cochrane; articles published until March 2016; with a populations, exposures and outcomes (PEO) search strategy was performed, focused on the issue: "In patients with periapical lesion to the implant during the osseointegration, what symptoms, signs, and changes in complementary examination manifested, for according to that stage, be intervened with the appropriate approach?". The set criteria for inclusion were peer-reviewed articles.

Results: From a total of 212 papers identified, 36 studies were included in this systematic review, with 15461 implants evaluated and 183 periapical implant lesions. Which 8 papers included more than 5 cases and 28 included equal or less than 5 cases. Analysis of the papers revealed that periapical implant lesion is classified according to evolution stages into acute (non-suppurated and suppurated) and subacute (or suppurated-fistulized). In the acute stage and in the subacute if there is no loss of implant stability, the correct treatment approach is implant periapical surgery. In the subacute stage associated with implant mobility the implant must be removed.

Conclusions: Evidence on the subject is very limited, there are few studies with small sample, without homogeneity of criteria for diagnosing the disease and without design of scientific evidence. Currently etiology lacks consensus. The early diagnosis of periapical implant periapical lesions during the osseointegration phase and early treatment, will lead to a higher survival rate of implants treated, hence preventing the need for implant extraction.

Key words: Apical peri-implantitis, retrograde peri-implantitis, inflammatory peri-implantitis lesion.

Introduction

Periapical implant lesion, also referred to as apical peri-implantitis or retrograde peri-implantitis, was first described by McAllister in 1992 (1) as an injury that occurs in the apical portion of an implant, causing failure of osseointegration. Sussman & Moss (2) defined it as the infectious-inflammatory process of the tissues surrounding the implant apex; and Quirynen *et al.* (3) as a clinically symptomatic periapical lesion that develops shortly after implant insertion while the coronal portion of the implant achieves a normal bone to implant interface.

The etiology of this lesion is not yet clear; however, several factors have been proposed that could be related to the onset of pathology. For some authors the most likely cause is the endodontic pathology of the tooth replaced by the implant or of the adjacent tooth (4-8). Other factors described were contamination of the implant surface (9,10), bone overheating during milling or preparation greater than the necessary for the implant (9,11,12) and pre-existing bone disease, presence of root fragments or foreign bodies (5,9,12).

The aim of this systematic review was to assess the papers to describe the concept, frequency, etiology, diagnosis, clinical classification, surgical procedure and prognosis.

Material and Methods

This systematic review was conducted in accordance with Preferred Reporting Items for Systematic Reviews and Meta-Analysis (PRISMA) (13). The study design was determined with a protocol by the authors before the review process.

- Focused question

Search strategy was performed with populations, exposures and outcomes (PEO) to synthesize the next focused question: “In patients with periapical lesion to the

implant during the osseointegration, what symptoms, signs, and changes in complementary examination develop, for according to that stage, be intervened with the appropriate approach?” (Table 1).

- Search method for identification of studies

Scientific papers were searched in PubMed, Web of Science and Cochrane. Manuscripts published until March 2016 were included. The following query was used: (((apical peri-implantitis)) OR (retrograde peri-implantitis)) OR (inflammatory peri-implantitis lesion)).

- Inclusion and exclusion criteria

Inclusion criteria were as follow: (1) populations: all human controlled clinical trials and prospective or retrospective clinical studies; (2) exposures: patients who have been studied the development of early failure or develop at least one periapical lesion implant, describing pathological condition and clinical intervention; (3) outcomes: frequency of the lesion, etiology, diagnosis, treatment and prognosis.

Exclusion criteria were as follow: (1) articles describing coronal peri-implantitis; (2) delayed complications or late implant failure; (3) reviews or update reviews.

- Data extraction and analysis

Titles and abstracts from the three search engines were downloaded to Mendeley software (Elsevier Inc, NY, USA). Mendeley was used to import the reference data, and to manage the imported references. Two reviewers (JB, JC) screened titles and abstracts independently of each other. Disagreement regarding inclusion was resolved by discussion. Full text manuscripts of the selected studies were obtained and further reviewed for inclusion. These were inserted into an excel work sheet. Papers were divided into two groups, with more than 5 cases and less than 5 cases.

Most of the included studies are observational studies without data collection protocols, case report or case series, with high risk of bias.

Table 1. Population, exposure, and outcomes (PEO) strategy.

Focus question	“Do patients with periapical lesion to the implant during the osseointegration, what signs, symptoms and evolution of the injury manifested, for according to that stage, be intervened with the appropriate approach?”
Population	Patients who had received a dental implant
Exposure or intervention	Patients who have developed periapical implant injury
Outcome	Resolution of disease. Prevalence, etiology, diagnosis, treatment and prognosis

Results

- Search results and study description

A total of 212 abstracts were retrieved and evaluated independently by two reviewers. A total of 36 publications were selected for the purpose of the systematic review (Fig. 1). Were evaluated a total of 15.461 implants, of which 183 periapical implant lesions were described. 8 publications included more than 5 cases (Tables 2,3) and 28 included 5 cases or less (Tables 4,5). The studies published were conducted at universities (30/36), hospital (3/36) or private practice centers (3/36).

adjacent tooth, clinical symptoms (pain and puffiness), signs (swelling, fistula) and radiological findings, percussion sound, diagnosis, treatment applied, pharmacology, success, failure and follow-up.

- Risk of Bias and Quality Assessment

Table 6 summarizes the quality of the studies, all articles (1,2,4,8,10-12,14-20) were classified as high bias.

- Frecuency

The frecuency of implant periapical lesion reported in the literature show considerable discrepancies between studies. Quirynen *et al.* (3), in a retrospective study on

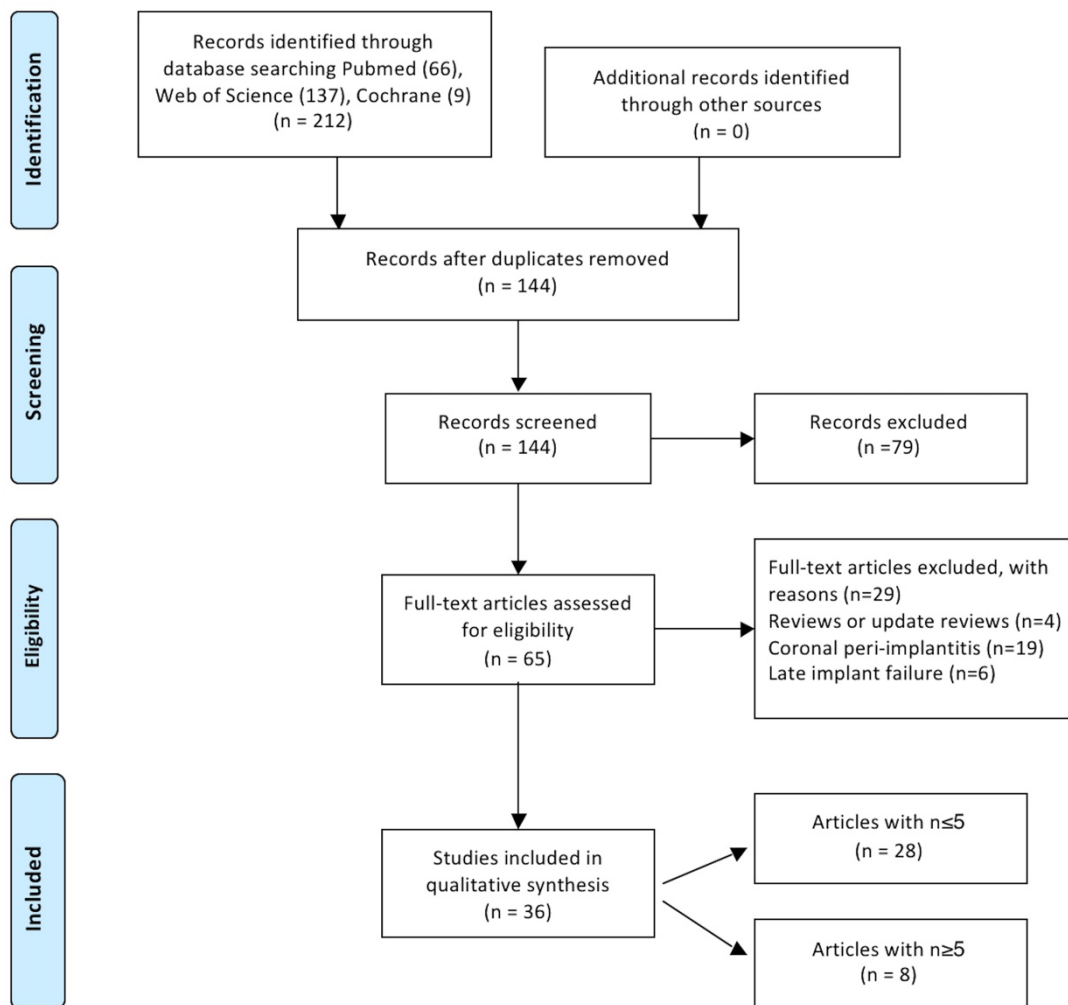


Fig. 1: Flow chart diagram of screened withdrawn and included articles through the review process.

- Description of study characteristics

Tables 2, 3, 4, 4 continue, 5, 5 continue present details to study settings. Reviewers extracted the following variables from the selected manuscripts: authors, year, setting (university/hospital/private practice), study design (retrospective/prospective), implants evaluated, periapical implant lesion, frequency, state prior tooth and the

539 implants, obtained an prevalence of 1.6% in maxilla and 2.7% in the mandible. Reiser & Nevins (4) found 10 cases in 3800 placed implants with an prevalence of 0.26%. Peñarrocha *et al.* (21) conducted a retrospective study including 5200 implants, of which 22 were diagnosed with implant periapical lesion, representing an prevalence of 0.4%. Zhou *et al.* (6) studied 128 im-

Table 2. Articles with n≥5, study design and diagnosis.

Authors	Year	Setting (type centre)	Study design	Implants evaluated	Periapical implant lesion	Upper jaw	Lower jaw	Frequency	Type of implant	Apical lesion in the previous tooth	Apical lesion in the adjacent tooth	Time of diagnosis	Pain	Swelling	Fistula	Radiolucence	Percussion sound	Diagnosis
Reiser <i>et al.</i>	1995	U	R	3800	10	-	-	0,26%										-
Quirynen M <i>et al.</i>	2005	U	R	539	10	7	3	1.6% upper jaw 2.7% lower jaw	TiUnite® (8/80) Machined implants (2/459)	7/10	-	1 month	2/10	4/10	6/10	10/10	-	-
Peñarrocha M <i>et al.</i>	2009	U	Pr	2500	7	3	4	-	ITI (6/7) Phibo(1/7)	-	-	7-15 days	7/7	3/7	0	5/7	3/7 dull percussion 4/7 non-evaluated (submerged)	acute non-suppurated (7/7)
Zhou W <i>et al.</i>	2009	U	Pr	128	10	6	4	7.8%	ITI (10/128)	-	with endodontic therapy (9/10)	-	-	Y	-	Y	-	-
Zhou Y <i>et al.</i>	2012	U	Pr	2987	6	-	6	-	ITI (6)	(1/6)	-	7-14 days (5/6) 1 month (1/6)	7/7	Y	-	Y	dull percussion	-
Lefever D <i>et al.</i>	2013	U	R	248	59	41	18	-	-	-	-	-	-	-	-	-	-	-
Peñarrocha MA <i>et al.</i>	2013	U	R	5200	22	14	8	-	ITI (6/22) Phibo (14/22)	-	-	mean period 18 days (6 days to 2 months)	17/22	8/22	3/22	15/22	17/22 timpnic percussion 5/22 non-evaluated (submerged)	acute non-suppurated (7/22) acute suppurated (12/22) subacute (3/22)
Stavaru M <i>et al.</i>	2014	H	R	11	11	7	4	-	-	2/11	-	first 6 months	7/11	-	-	-	-	-

U (University); H (Hospital); P (Private); Pr (Prospective); R (Retrospective); Y (Yes).

Table 3. Articles with n≥5, treatment and follow-up.

Authors	Apical curettage	Irrigation	Local agent	Implant apex resection	Regeneration materials	Pharmacology	Histology	Bacteria	Success	Failure	Follow-up
Reiser <i>et al.</i>	-	-	-	-	-	-	-	-	-	-	-
Quirynen M <i>et al.</i>	Y	-	-	-	Bio-Oss® (4/10)	β-lactamase-resistant penicillins	-	-	-	1/10 (18months)	-
Peñarrocha M <i>et al.</i>	Y	sterile saline solution	-	-	When necessary, Bio-Oss or bone shavings from surgical field	500 mg amoxicilline 3x/day 7 days	3 cases with sufficient material	-	-	0	1 to 6 years
Zhou W <i>et al.</i>	3/10 surgery 7/10 repeated endodontic treatment adjacent tooth	-	-	-	BioOss(2/3) Membrane (2/3)	-	-	-	-	1/3 surgically treated 4/7 endodontically treated	-
Zhou Y <i>et al.</i>	Y	sterile saline solution + chlorhexidine	Tetracycline paste	-	N	cefuroxime 1.5g 2x/day + metronidazole 100ml each day (in vein) before and after surgery	-	-	-	0	12 to 36 months
Lefever D <i>et al.</i>	Curettage (11/59) curettage + autogenous bone (2/59)	curettage + systemic antibiotics (10/59) curettage + barrier membrane (2/59) only antibiotics (2/59) explantation (17/59) no treatment (2/59)		-	-	-	-	Y	27/59	to 126 months	-
Peñarrocha MA <i>et al.</i>	Y	sterile saline solution	-	-	N	500 mg amoxicilline with 125 mg clavulanic acid every 8h 7 days 600 mg ibuprofen every 8 hours for 4 days 0,12% chlorhexidine digluconate 3x/day for 7 days	-	-	survival rate 91.0%	-	time average 20.1 months (range, 12 to 72 months)
Stavaru M <i>et al.</i>	7/11	N	N	3/11	3/11 collagen reservable membranes 2/11 particulate alveolar bone autograft 1/11 artificial bone of bovine origin	-	-	-	-	1/7	1 to 4 years

Y (Yes); N (No).

Table 4. Articles with n<5, study design and diagnosis.

Authors	Year	Setting (type centre)	Study design	Implants evaluated	Periapical implant lesion	Upper jaw	Lower jaw	Type of implant	Apical lesion in the previous tooth	Apical lesion in the adjacent tooth	Time of diagnosis	Pain	Swelling	Fistula	Radiolucence	Percussion sound	Mobility	Diagnosis
McAllister <i>et al.</i>	1992	U	Case series	5	5	5	-	-	Y	N	3 months	-	-	Y	-	-	-	-
Sussman, HI; Moss, SS	1993	U	Case report	1	1	-	1	Screw Vent, Dentsply	Y	Y	2 weeks	Y	-	-	Y	-	-	-
Bretz <i>et al.</i>	1997	U	Case report	1	1	1	-	-	-	-	-	-	-	-	-	-	-	-
Sussman HI <i>et al.</i>	1998	U	Case series	4	4	1	3	-	2/4	2/4	1 month	-	-	-	-	-	-	-
Piatelli A <i>et al.</i>	1998	U	Case report	1	1	1	-	Brånemark	N	N	1 month	-	-	Y	Y (7 months)	-	-	-
Scarano A <i>et al.</i>	2000	U	Case report	1	1	-	1	-	N	N	6 month	Y	-	N	Y	-	-	-
Chaffee NR <i>et al.</i>	2001	U	Case report	1	1	-	1	-	N	Y	35 days	Y	-	N	Y	-	-	-
Ayungco L <i>et al.</i>	2001	P	Case series	3	3	2	1	Brånemark	3/3	1/3	1 month	1/3	3/3	1/3	3/3	-	-	-
Brisman AS	2001	H	Case series	4	4	4	-	-	4/4	4/4	1 week (Case 1) 2 weeks (Case 2)	2/4	4/4	1/4	4/4	-	1/4	-
Flanagan D <i>et al.</i>	2002	P	Case report	1	1	1	-	-	-	Y	10 weeks	Y	Y	Y	Y	-	-	-
Oh TJ <i>et al.</i>	2003	U	Case report	1	1	-	1	Brånemark	Y	Y	-	-	Y	Y	Y (3 months)	-	Y	-
Park SH <i>et al.</i>	2004	U	Case series	2	2	2	-	Brånemark	Y	Y	-	N	Y	1/2 (22 days)	Y	-	N	-
Tseng CC <i>et al.</i>	2005	U	Case report	1	1	-	1	ITI	-	Y	N	-	-	-	Y (6 months)	-	Y	-
Tözüm TF <i>et al.</i>	2006	U	Case report	1	1	1	-	-	Y	Y	-	N	-	Y	Y (2 months)	-	-	-
Ataullah <i>et al.</i>	2006	U	Case report	1	1	1	-	Brånemark	Y	N	2 months	Y	Y	N	Y	-	N	-

U (University); H (Hospital); P (Private); Y (Yes); N (No).

Table 4 continue. Articles with n<5, study design and diagnosis.

Nedir R et al.	2007	U	Case report	1	1	1	1	1	-	Straumann	Y	N	-	N	Y	Y (3.5 years)	-	N	-
Dahlin C et al.	2008	H	Case series	2	2	1	1	1	1	Brånemark	N	N	-	N	-	Case 1: 1 year Case 2: 2 years	-	-	-
Rokadiya S et al.	2008	U	Case report	1	1	-	1	1	1	-	-	-	7 days	-	N	Y (17 days)	-	-	acute osteomyelitis
Chang LC et al.	2009	U	Case series	2	2	-	2	2	2	Biomet 3i	N	N	1 month	N	Y	Y	-	-	-
Flanagan D	2009	P	Case series	2	2	2	2	2	-	Implant Direct	2/2	-	4 and 8 weeks	Y	Y	Y	-	N	-
Silva GC et al.	2010	U	Case series	2	2	1	1	1	1	Biomet 3i	-	-	-	N	-	Y (Case 1: 1 year; Case 2: 3 months)	-	N	-
Waasdorp J et al.	2010	U	Case report	1	1	-	1	1	1	Nobel Biocare	Y	Y	-	N	-	Y	-	-	-
Chan HL et al.	2011	U	Case series	2	2	2	2	2	-	-	Y	Y	-	N	-	Y (3 months)	-	N	-
Mohamed J	2012	U	Case report	1	1	1	1	1	-	-	Y	Y	-	N	-	Y	-	N	-
Quaranta A et al.	2014	U	Case report	1	1	1	1	1	-	Sweden & Martina	Y	-	3 months	Y	Y	Y	-	N	-
Buhara A et al.	2014	U	Case series	2	2	-	2	2	2	Astra Tech	-	-	Case 1: 20 days Case 2: 1 day	Y	N	Y	-	N	-
Jafarian M et al.	2016	U	Case report	2	2	-	2	2	2	Nobel Biocare	-	-	10 days + mental nerve paraesthesia	Y	Y	Y	-	N	-
Tozlim T et al.	2016	U	Case report	1	1	1	1	1	-	Zimmer	-	Y	9 months	N	Y	Y (9 months)	-	N	-

U (University); H (Hospital); P (Private); Y (Yes); N (No).

Table 5. Articles with n<5, treatment and follow-up.

Authors	Apical curettage	Irrigation	Local agent	Implant apex resection	Regeneration materials	Explantation	Pharmacology	Histology	Bacteria	Failure	Follow-up
McAllister <i>et al.</i>	Y	-	citric acid + tetracycline paste	-	DFDBA + barrier membrane	-	amoxicillin + metronidazole	-	-	-	4 months
Sussman, HI; Moss, SS	-	-	-	-	-	1	-	-	-	1	-
Bretz <i>et al.</i>	-	-	chlorhexidine	-	DFDBA	-	-	-	-	-	17 months
Sussman HI <i>et al.</i>	-	-	-	-	-	-	-	-	-	-	-
Piatelli A <i>et al.</i>	-	-	-	-	-	1	metronidazole	Y	-	1	-
Scarano A <i>et al.</i>	-	-	-	-	-	1	-	-	-	1	-
Chaffee NR <i>et al.</i>	Y	-	-	-	DFDBA + barrier membrane	-	500 mg amoxicillin 3 times daily 10 days	Y	-	0	-
Ayango L <i>et al.</i>	3/3	sterile saline solution	tetracycline paste	-	-	-	500 mg amoxicillin 3 times daily 7 days	-	-	0	8 months to 8 years
Brisman AS	1/4	-	-	-	-	3/4	300 mg clindamycin 4 times daily 7 days	-	-	3	-
Flanagan D <i>et al.</i>	Y	-	paste of calcium hydroxide	-	-	-	500 mg penicillin aid for 7 days + hydrocodone	-	-	0	11 months
Oh TJ <i>et al.</i>	-	-	-	-	-	1	-	-	-	1	-
Park SH <i>et al.</i>	Y	sterile saline solution	-	-	DFDBA mixed with 250 mg tetracycline	1 + reimplantation	500 mg amoxicillin 3 times daily for 14 days	-	-	1	-
Tseng CC <i>et al.</i>	Y	-	-	-	Bio-Oss®	1	-	Y	-	1	-
Tüzüm TF <i>et al.</i>	Y	sterile saline solution	-	-	calcium sulfate + membrane	-	500 mg amoxicillin 4 times daily 10 days + 0.2% chlorhexidine	-	-	-	6 months
Ataullah <i>et al.</i>	Y	sterile saline solution	-	-	Bio-Oss® + Bio-Gide®	-	500 mg amoxicillin 3 times daily 7 days + chlorhexidine	-	-	-	-
Nedir R <i>et al.</i>	Y	-	-	Y	-	-	750 mg amoxicillin 3 times daily 12 days	Y	-	-	2 years
Dahlin C <i>et al.</i>	Y	sterile saline solution	-	Y (2/2)	-	-	300 mg clindamycin 3 times daily for 5 days	-	-	-	Case 1: 1 year Case 2: 3 years

DFDBA (demineralized freeze-dried bone allografts); Y (Yes).

Table 5 continue. Articles with n<5, treatment and follow-up.

<i>Rokadiya S et al.</i>	-	-	-	-	-	-	-	-	1	-	Y	1	-
<i>Chang LC et al.</i>	-	-	-	-	-	-	-	-	-	fluxloxacillin 250 mg amoxicillin 500 mg acetaminophen (every 8 hours 3 days), prednisolone (5 mg 3 times daily 3 days), augmentin 375 mg metenamic acid 250 mg (3 times daily 7 days)	-	-	2 years
<i>Flanagan D</i>	Y	sterile saline solution	calcium hydroxide	-	-	allograft + barrier membrane	-	-	-	-	-	-	-
<i>Silva GC et al.</i>	Y	sterile saline solution	-	-	-	-	2	-	-	-	-	-	-
<i>Waasdorp J et al.</i>	-	-	-	-	-	-	-	-	-	antibiotic treatment	-	-	1 year
<i>Chan HL et al.</i>	Y	0.12% chlorhexidine	-	-	allograft + 250mg tetracycline powder and 0.9% saline	-	-	-	-	-	Y	-	6 months
<i>Mohamed J</i>	Y	-	universal implant deplaquer (Straumann)	-	-	xenograft + platelet rich fibrin	-	-	-	-	-	-	1 year
<i>Quaranta A et al.</i>	Y	sterile saline solution	tetracycline paste (250 mg powder)	-	-	pericardium membrane	-	-	-	1000mg penicillin 3 times a day for 7 days	-	-	5 years
<i>Buhara A et al.</i>	-	sterile saline solution	-	-	-	-	2	-	-	clindamycin	-	2	-
<i>Jafarian M et al.</i>	Y	sterile saline solution	-	-	xenograft + resorbable collagen membrane	-	-	-	-	300mg clindamycin 3 times daily 10 days + 500mg amoxicillin 3 times daily 10 days + 0.2% chlorhexidine	-	-	6 months
<i>Toziüm T et al.</i>	Y	sterile saline solution + 0.12% chlorhexidine	ultrasonic scaler	-	-	xenogenic graft material + resorbable membrane. 4 weeks recurrence of fistula: xenogenic graft material + platelet rich fibrin + resorbable membrane	-	-	-	500 mg metronidazole 2 times daily for 10 days	-	-	1 year

DFDBA (deminerlized freeze-dried bone allografts); Y (Yes).

Table 6. Assessment of the risk of bias.

Author	Random sequence generation	Allocation concealment	Blinding	Incomplete outcome data	Selective reporting
McAllister <i>et al.</i> (1)	-	-	-	-	-
Sussman <i>et al.</i> (2)	-	-	-	-	-
Reiser <i>et al.</i> (4)	-	-	-	-	-
Bretz <i>et al.</i> (37)	-	-	-	-	-
Sussman HI (23)	-	-	-	-	-
Piatelli A <i>et al.</i> (17)	-	-	-	-	-
Scarano A <i>et al.</i> (11)	-	-	-	-	-
Chaffee NR <i>et al.</i> (12)	-	-	-	-	-
Ayangco L <i>et al.</i> (10)	-	-	-	-	-
Brisman AS (8)	-	-	-	-	-
Flanagan D <i>et al.</i> (36)	-	-	-	-	-
Oh TJ <i>et al.</i> (18)	-	-	-	-	-
Park SH <i>et al.</i> (28)	-	-	-	-	-
Quirynen M <i>et al.</i> (3)	-	-	-	-	-
Tseng C <i>et al.</i> (38)	-	-	-	-	-
Tözüm TF <i>et al.</i> (29)	-	-	-	-	-
Ataullah <i>et al.</i> (16)	-	-	-	-	-
Nedir R <i>et al.</i> (30)	-	-	-	-	-
Dahlin C <i>et al.</i> (34)	-	-	-	-	-
Rokadiya S <i>et al.</i> (31)	-	-	-	-	-
Chang LC <i>et al.</i> (20)	-	-	-	-	-
Peñarrocha M <i>et al.</i> (26)	-	-	-	-	-
Flanagan D (21)	-	-	-	-	-
Zhou W <i>et al.</i> (6)	-	-	-	-	-
Silva GC <i>et al.</i> (24)	-	-	-	-	-
Waasdorp J <i>et al.</i> (19)	-	-	-	-	-
Chan HL <i>et al.</i> (18)	-	-	-	-	-
Mohamed J <i>et al.</i> (19)	-	-	-	-	-
Jung RE <i>et al.</i> (22)	-	-	-	-	-
Zhou Y <i>et al.</i> (32)	-	-	-	-	-
Lefever D <i>et al.</i> (15)	-	-	-	-	-
Peñarrocha MA <i>et al.</i> (42)	-	-	-	-	-
Quaranta A <i>et al.</i> (20)	-	-	-	-	-
Kutlu HB <i>et al.</i> (33)	-	-	-	-	-
low risk (+); high risk (-)					

plants with adjacent teeth that had received endodontic treatment, the incidence reported was 7.8%. Studies are required with more patients to provide more data on the frequency of periapical implant lesion.

- Etiology

Different etiological factors have been suggested for periapical implant lesion, although evidence is very limited. According to the source of contamination: a) contamination of the surgical bed: implant surface contamination (9,10), overheating of bone during drilling (9,11). b) pre-existing pathology: immediate post-extraction placement (21), endodontic pathology associated with the extracted tooth or adjacent teeth (6,8,22), pre-existing bone pathology (6), and presence of root remains or foreign bodies (9,12).

Some authors (9,21) relate immediate implant placement after tooth extraction with apical pathology and the onset of periapical periimplantitis. Brisman *et al.* (8) associated the failure of four implants to the existence of adjacent endodontically treated teeth, which were asymptomatic and showed no radiographic signs of pathology. Lefever *et al.* (22) obtained statistical significance between the onset of apical peri-implantitis and the existence of neighboring teeth with signs of apical pathology compared to adjacent teeth without apical lesions. These authors suggest that the distance between teeth and implants is important for the development of these infections.

- Diagnosis

Diagnosis of implant periapical lesions involves clinical and radiographic assessments. The symptoms (pain and puffiness) and signs (swelling, fistula and drainage) may appear with different intensity depending on the stage of the lesion. Radiographically, radiolucency around the implant apex may be observed.

Regarding at the time that this condition is detected, the studies have described the radiological findings usually appear between 7 and 16 days after surgery (6,21,23), some cases described the appearance until 3 months after implant placement (11,16,24,25). Other authors (3,5,14,22,26-29) do not specify the exact timing of detection, they mentioned that the finding was before prosthetic loading.

- Clinical classification

No consensus exists about how to classify the lesion. Have been proposed four different classifications.

Reiser & Nevins (4) classified the injuries as inactive (not infected) and infected. Sussman (14) divided the nature of lesions as follows: implant to tooth when produced during implant insertion (type I) and tooth to implant when implant apical lesion occurred due to infection of adjacent teeth to the implant that can be contaminated the apical part of the implant (type II). Kadkhodazadeh *et al.* (30) in 2013 introduced a new classification about relationship between periodontal,

periapical, and peri-implant complications, only the condition of the implant apical lesion is applied, does not consider development time. Peñarrocha *et al.* (31) described the disease into 3 stages: non-suppurative; suppurative; and subacute. These stages are based on the similarity with the tooth periapical pathology.

In implants, the most important difference is that not exist periodontal ligament, implant fixation to bone differs. The non-suppurative phase has acute symptoms, spontaneous, moderate-severe, continuous, localized in apex implant, however, pain does not increase with the mastication. Mucosa can be swelled and reddish, implant percussion produces a tympanic sound, without increasing pain. No radiographic changes are observed in this initial phase.

In the suppurative phase, symptoms and signs are the same as in non-suppurated, but may appear periimplant radiolucent area radiographically.

Subacute phase is characterized by dull pain, with possible fistulous tract, buccal abscess or suppuration around the implant neck. Percussion produces a tympanic sound when the process fistulizes and the implant remains stable and a dull sound to percussion is produced when there is bone destruction around the implant, therefore, the implant may have mobility. Radiographically, the radiolucent area of the implant body may be associated with the destruction along the implant. The difference of this phase between the tooth and the implant, is that not having periodontal ligament, purulent material find the area with less pressure to drain along the axis of the implant, creating a detachment of the implant with a loss of fixation (31).

In a case series study (21) of 22 implant periapical lesion, described the most frequent stage of the disease as suppurative (60%) followed by the non-suppurative phase (35%) and the subacute phase (5%). The process is evolutionary, from non-suppurative phase to subacute phase with losing fixation and implant failure.

- Treatment

• Pharmacology

The following antibiotics have been used in the reviewed articles on treatment of implant periapical lesions: amoxicillin (5,10,12,23,27,32-36), amoxicillin/clavulanate (21), metronidazole (16,37,38) and clindamicine (8,39).

In some published case series (5,39), initial treatment with antibiotics was not effective to control symptomatic or active lesions, which required surgical access. Romanos *et al.* (40) concluded in their review that antibiotic treatment alone is not effective.

• Surgical procedure

The surgical treatment comprises: infiltrative anesthesia, incision, full-thickness flap, osteotomy, apical curettage of granulation tissue and profuse irrigation.

Some authors after remove granulation tissue, irrigate

with sterile saline solution (1,5,16) or chlorhexidine (6,24). Other agents have been suggested for topical decontamination of the implant surface, such as chlorhexidine (5,6,24), calcium hydroxide paste (17) or tetracycline paste (6,10,16,24), but there are no evidence of the efficacy of any of them.

Some studies reported the use of bone regeneration materials, accompanied or not with tissue regeneration barriers, in order to achieve complete bone regeneration of the defect (3,15,17,24,34,41). Sectioning of the implant apex has been suggested in those cases in which total removal of the granular tissue is not assured otherwise (16,24,39). Depending on the state of the adjacent pieces is recommended root-canal therapy or periapical surgery if the adjacent tooth was endodontically treated (6,34).

- Prognosis

The prognosis for these lesions is favorable, the literature describes a survival of 73.2% to 97.4% of the implants treated with a maximum follow-up of 4.5 years (5,21,22,42). Success depends on early diagnosis and adequate remaining bone fixation. The implementation of the new imaging technologies, CBCT, provide benefits in the early diagnosis, showing a clear clinical image of the periimplant bone loss (43).

Discussion

The frequency of this lesion is low as described in the literature (3,4,6,21). Must be taken into account that the available articles are retrospective, another methodological design and the largest study of this lesion could increase its frequency within the early implant failures. Regarding etiology, inflammatory-infectious origin can be delimited to factors of contamination of the surgical bed and/or pre-existing pathology. Oral surgery is a non-aseptic surgery, still using sterility protocols. Implant surface may become contaminated with saliva, epithelial cells or lubricant oil from the rotary material (9,10). Another factor that may be neglected during surgery is the overheating of the bone, due to an inadequate irrigation or an excessive time during the tilling of the surgical bed (9,11).

It is difficult to exclude the existence of remaining bone pathology, such as a residual cyst, after tooth extraction in the space where the implant will be placed. Neither periapical x-ray or panoramic radiograph are able to detect a radiolucent area if the injury does not destroy the osseous cortical (44). It is recommended the diagnosis with CBCT, however, it is not easy to diagnose small residual lesions in the bone.

The development of this lesion is early (6,21,23), so follow-up after implant placement is a key factor to properly diagnose and treat the pathological condition. Accordance with Peñarrocha et. al. (45), therapeutic option is decided according to the evolution of the periapical

implant lesion, based on clinical diagnosis and radiological explorations. Periimplant radiolucencies may be casual findings during routine radiographic assessments. If the patient is asymptomatic and the diameter of the radiolucent area is small, it is not necessary to treat the lesion; over-preparation of the implant bed is the most probable cause, and only periodic radiographic controls should be done. If in the controls, the radiolucency has increased in size or the patient develops pain, the surgical treatment will be applied.

If after placing an implant appears localized pain in periimplant area, with or without radiographic changes, should be considered as an inflammatory periapical implant pathology, acute non-suppurative or suppurative. In any of these cases, is indicated apical implant curettage to remove the granulation tissue.

Pharmacological treatment is based on antibiotics for at least one week, the combination of a broad spectrum antibiotic such as amoxycillin against anaerobes with another effective as metronidazole.

Limitations of the present study

Regard to the level of bias in the studies, several limitations should be considered about the design of the studies because it was not possible the application of quality questionnaires. First, all final articles obtained were a case report or case series, thus the risk of bias was high. Second, the low prevalence and limited knowledge of the lesion. Third, absence of homogeneity of data. It is necessary data collection protocol during the osseointegration phase for future studies.

Conclusions

Evidence on the subject is very limited, currently etiology lacks consensus. If after placing an implant appears localized pain in periapical area, with or without radiographic changes, should be considered periapical implant pathology. The early diagnosis of periapical implant lesions during the osseointegration phase and early surgical treatment, will lead to a higher survival rate of implants treated, hence preventing the need for implant extraction.

References

1. McAllister BS, Masters D, Meffert RM. Treatment of implants demonstrating periapical radiolucencies. *Pract Periodontics Aesthet Dent.* 1992;4:37-41.
2. Sussman HI, Moss SS. Localized osteomyelitis secondary to endodontic-implant pathosis. A case report. *J Periodontol.* 1993;64:306-10.
3. Quirynen M, Vogels R, Alsaadi G, Naert I, Jacobs R, van Steenberghe D. Predisposing conditions for retrograde peri-implantitis, and treatment suggestions. *Clin Oral Implants Res.* 2005;16:599-608.
4. Reiser GM, Nevins M. The implant periapical lesion: etiology, prevention, and treatment. *Compend Contin Educ Dent.* 1995;16:768, 770, 772 passim.
5. Peñarrocha-Diago M, Boronat-Lopez A, García-Mira B. Inflammatory implant periapical lesion: etiology, diagnosis, and treatment-presentation of 7 cases. *J Oral Maxillofac Surg.* 2009;67:168-73.

6. Zhou W, Han C, Li D, Li Y, Song Y, Zhao Y. Endodontic treatment of teeth induces retrograde peri-implantitis. *Clin Oral Implants Res.* 2009;20:1326-32.
7. Temmerman A, Lefever D, Teughels W, Balshi TJ, Balshi SF, Quirynen M. Etiology and treatment of periapical lesions around dental implants. *Periodontol* 2000. 2014;66:247-54.
8. Brisman DL, Brisman AS, Moses MS. Implant failures associated with asymptomatic endodontically treated teeth. *J Am Dent Assoc.* 2001;132:191-5.
9. Esposito M, Hirsch J, Lekholm U, Thomsen P. Differential diagnosis and treatment strategies for biologic complications and failing oral implants: a review of the literature. *Int J Oral Maxillofac Implants.* 14:473-90.
10. Ayango L, Sheridan PJ. Development and treatment of retrograde peri-implantitis involving a site with a history of failed endodontic and apicoectomy procedures: a series of reports. *Int J Oral Maxillofac Implants.* 2001;16:412-7.
11. Scarano A, Di Domizio P, Petrone G, Iezzi G, Piattelli A. Implant periapical lesion: a clinical and histologic case report. *J Oral Implantol.* 2000;26:109-13.
12. Chaffee NR, Lowden K, Tiffée JC, Cooper LF. Periapical abscess formation and resolution adjacent to dental implants: a clinical report. *J Prosthet Dent.* 2001;85:109-12.
13. Liberati A, Altman DG, Tetzlaff J, Mulrow C, Gøtzsche PC, Ioannidis JPA, et al. The PRISMA statement for reporting systematic reviews and meta-analyses of studies that evaluate health care interventions: explanation and elaboration. *J Clin Epidemiol.* 2009;62:e1-34.
14. Sussman HI. Periapical implant pathology. *J Oral Implantol.* 1998;24:133-8.
15. Bretz WA, Matuck AN, de Oliveira G, Moretti AJ, Bretz WA. Treatment of retrograde peri-implantitis: clinical report. *Implant Dent.* 1997;6:287-90.
16. Piattelli A, Scarano A, Balleri P, Favero GA. Clinical and histologic evaluation of an active 'implant periapical lesion': a case report. *Int J Oral Maxillofac Implants.* 1998;13:713-6.
17. Flanagan D. Calcium hydroxide paste as a surface detoxifying agent for infected dental implants: two case reports. *J Oral Implantol.* 2009;35:204-9.
18. Oh TJ, Yoon J, Wang HL. Management of the implant periapical lesion: a case report. *Implant Dent.* 2003;12:41-6.
19. Mohamed JB, Alam MN, Singh G, Chandrasekaran SC. The management of retrograde peri-implantitis: a case report. *J Clin Diagn Res.* 2012;6:1600-2.
20. Quaranta A, Andreana S, Pompa G, Procaccini M. Active implant peri-apical lesion: a case report treated via guided bone regeneration with a 5-year clinical and radiographic follow-up. *J Oral Implantol.* 2014;40:313-9.
21. Peñarrocha-Diago M, Maestre-Ferrín L, Peñarrocha-Oltra D, Canullo L, Piattelli A, Peñarrocha-Diago M. Inflammatory implant periapical lesion prior to osseointegration: a case series study. *Int J Oral Maxillofac Implants.* 2013;28:158-62.
22. Lefever D, Van Assche N, Temmerman A, Teughels W, Quirynen M. Aetiology, microbiology and therapy of periapical lesions around oral implants: a retrospective analysis. *J Clin Periodontol.* 2013;40:296-302.
23. Atallah K, Chee LF, Peng LL, Lung HHK. Management of retrograde peri-implantitis: a clinical case report. *J Oral Implantol.* 2006;32:308-12.
24. Chan H-L, Wang H-L, Bashutski JD, Edwards PC, Fu J-H, Oh T-J. Retrograde peri-implantitis: a case report introducing an approach to its management. *J Periodontol.* 2011;82:1080-8.
25. Waasdorp J, Reynolds M. Nonsurgical treatment of retrograde peri-implantitis: a case report. *Int J Oral Maxillofac Implants.* 2010;25:831-3.
26. Chang L-C, Hsu C-S, Lee Y-L. Successful medical treatment of an implant periapical lesion: a case report. *Chang Gung Med J.* 2011;34:109-14.
27. Flanagan D. Apical (retrograde) peri-implantitis: a case report of an active lesion. *J Oral Implantol.* 2002;28:92-6.
28. Jung RE, Zaugg B, Philipp AOH, Truninger TC, Siegenthaler DW, Hämmerle CHF. A prospective, controlled clinical trial evaluating the clinical radiological and aesthetic outcome after 5 years of immediately placed implants in sockets exhibiting periapical pathology. *Clin Oral Implants Res.* 2013;24:839-46.
29. Silva GC, Oliveira DRF, Vieira TC, Magalhães CS, Moreira AN. Unusual presentation of active implant periapical lesions: a report of two cases. *J Oral Sci.* 2010;52:491-4.
30. Kadkhodazadeh M, Amid R. A New Classification for the Relationship between Periodontal, Periapical, and Peri-implant Complications. *Iran Endod J.* 2013;8:103-8.
31. Peñarrocha Diago M, Boronat López A, Lamas Pelayo J. Update in dental implant periapical surgery. *Med Oral Patol Oral y Cir Bucal.* 2006;11:E429-32.
32. Siegenthaler DW, Jung RE, Holderegger C, Roos M, Hämmerle CHF. Replacement of teeth exhibiting periapical pathology by immediate implants: a prospective, controlled clinical trial. *Clin Oral Implants Res.* 2007;18:727-37.
33. Park S. Management and Prevention of Retrograde Peri-Implant Infection from Retained Root Tips: Two Case Reports. 2004.
34. Tözüm TF, Sençimen M, Ortakoğlu K, Ozdemir A, Aydin OC, Keleş M. Diagnosis and treatment of a large periapical implant lesion associated with adjacent natural tooth: a case report. *Oral Surg Oral Med Oral Pathol Oral Radiol Endod.* 2006;101:e132-8.
35. Nedir R, Bischof M, Pujol O, Houriet R, Samson J, Lombardi T. Starch-induced implant periapical lesion: a case report. *Int J Oral Maxillofac Implants.* 2007;22:1001-6.
36. Rokadiya S, Malden NJ. An implant periapical lesion leading to acute osteomyelitis with isolation of *Staphylococcus aureus*. *Br Dent J.* 2008;205:489-91.
37. Zhou Y, Cheng Z, Wu M, Hong Z, Gu Z. Trepanation and curettage treatment for acute implant periapical lesions. *Int J Oral Maxillofac Surg.* 2012;41:171-5.
38. Kutlu HB, Genc T, Tozum TF. Treatment of Refractory Apical Peri-Implantitis: A Case Report. *J Oral Implantol.* 2016;42:104-9.
39. Dahlin C, Nikfarid H, Alsén B, Kashani H. Apical peri-implantitis: possible predisposing factors, case reports, and surgical treatment suggestions. *Clin Implant Dent Relat Res.* 2009;11:222-7.
40. Romanos GE, Froum S, Costa-Martins S, Meitner S, Tarnow DP. Implant periapical lesions: etiology and treatment options. *J Oral Implantol.* 2011;37:53-63.
41. Tseng C, Chen Y-HM, Pang I-C, Weber H. Peri-implant pathology caused by periapical lesion of an adjacent natural tooth: a case report. *Int J Oral Maxillofac Implants.* 2005;20:632-5.
42. Balshi SF, Wolfinger GJ, Balshi TJ. A retrospective evaluation of a treatment protocol for dental implant periapical lesions: long-term results of 39 implant apicoectomies. *Int J Oral Maxillofac Implants.* 2007;22:267-72.
43. Gupta S, Patil N, Solanki J, Singh R, Laller S. Oral Implant Imaging: A Review. *Malays J Med Sci.* 22:7-17.
44. Bender IB, Seltzer S. Roentgenographic and direct observation of experimental lesions in bone. I. 1961. *J Endod.* 2003;29:702-6; discussion 701.
45. Peñarrocha-Diago M, Maestre-Ferrín L, Cervera-Ballester J, Peñarrocha-Oltra D. Implant periapical lesion: diagnosis and treatment. *Med Oral, Patol Oral y Cir Bucal.* 2012;17:e1023-7.

Conflict of Interest

The authors declare that they have no conflict of interest.